

STS/EACTS Latin America Cardiovascular Surgery Conference

November 15-17, 2018

Hilton Cartagena | Cartagena, Colombia



The Society
of Thoracic
Surgeons



EACTS
European Association for
Cardio-Thoracic Surgery



HOSPITAL ITALIANO
de Buenos Aires

Instituto de Medicina
Cardiovascular

Current Surgical Strategies in the Management of Tricuspid Valve Endocarditis

Vadim Kotowicz, MD
Chief of Cardiovascular Service
Italian Hospital of Buenos Aires

Disclosure

Medtronic inc. Consulting

Johnson & Johnson Advisory Board

Edwards Lifesciences Corp. Consulting

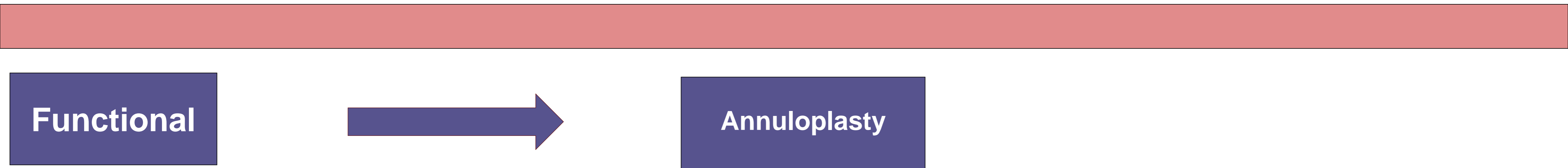
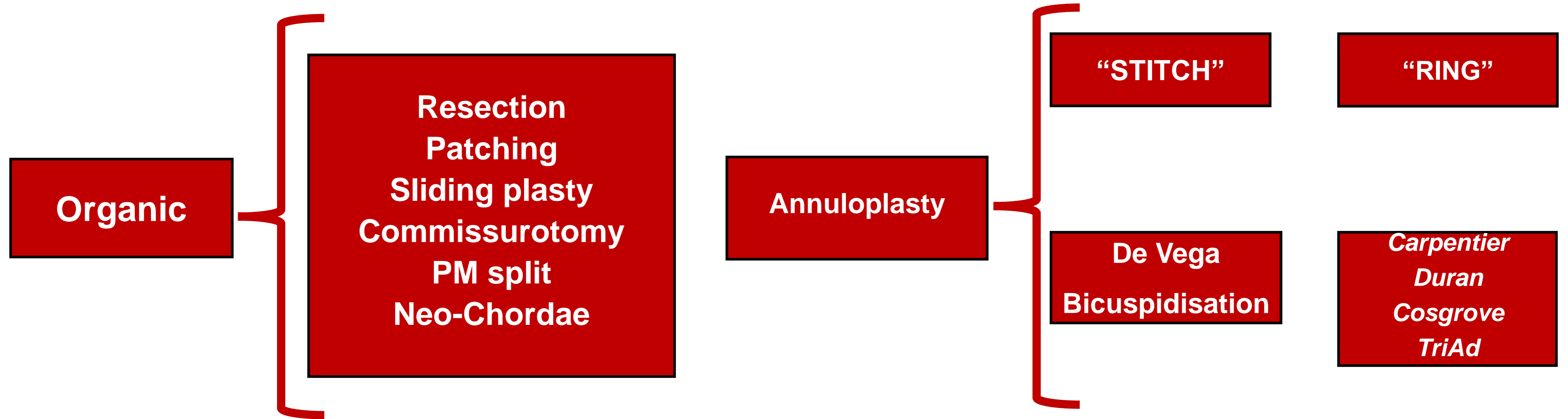
Functional vs Organic Tricuspid valve Regurgitation

- **Functional TR is secondary to pulmonary HTN or left sided lesions (usually MS / MR):**
 - Normal leaflets
 - Dilated TV annulus
- **Organic TR is secondary to TV disease:**
 - Rheumatic heart disease
 - Acute endocarditis
 - Trauma (incl. iatrogenic)
 - Ebstein's anomaly
 - Carcinoid syndrome

Repair

Repair
/Replacement

Type of valve Repair



TRICUSPID VALVE ENDOCARDITIS

- **INTRAVENOUS DRUGS USER**
- **Cardiac implantable electronic device infection**
- **Indwelling lines:**

➔ 30-40%

➔ 40-50%

➔ 8-10%

60-90%

Staphylococcus Aureus
Pseudomonas aeruginosa

gram-negative microorganisms
Fungi
polymicrobial infections

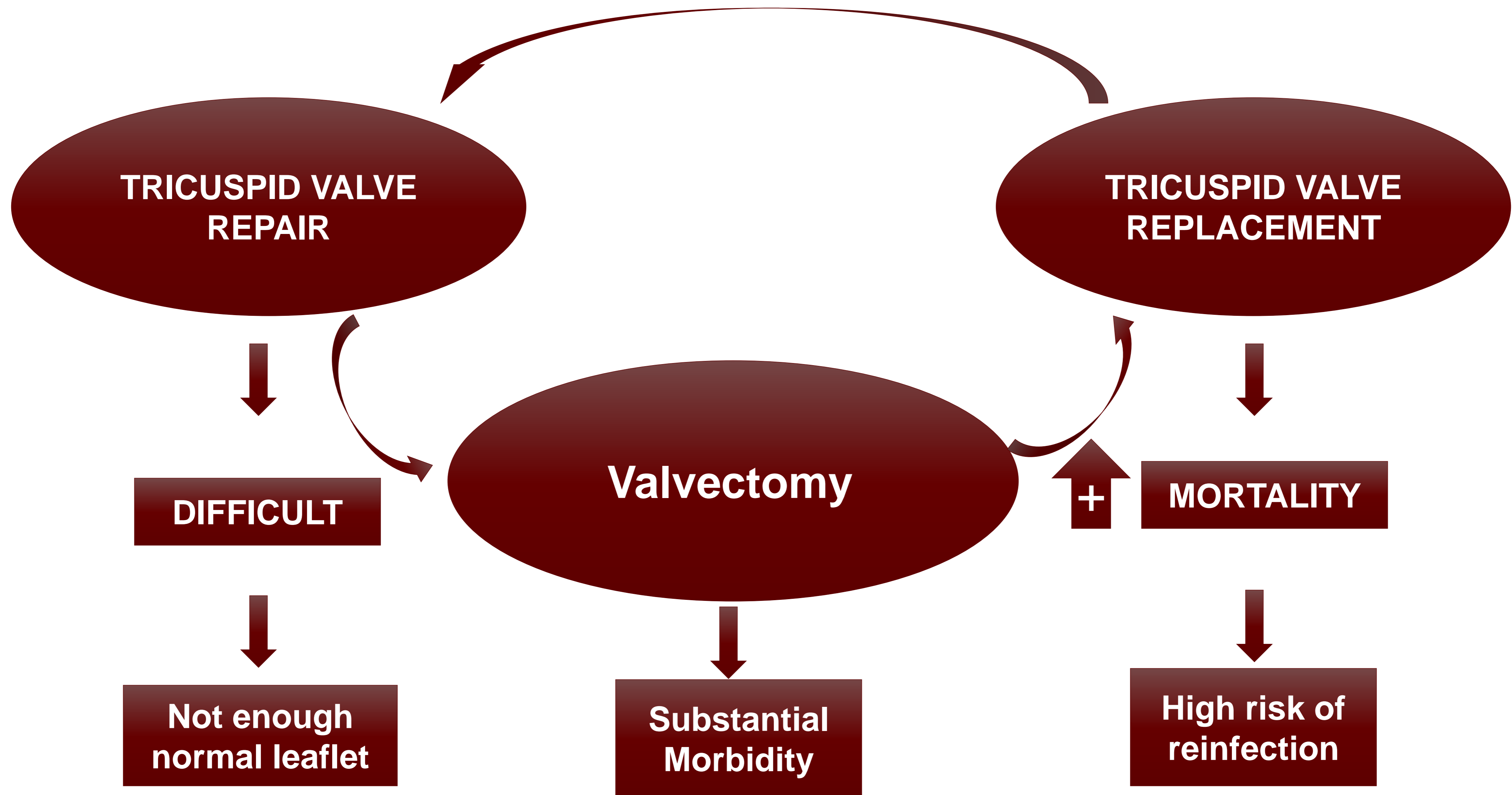
Less frequently

Hemodialysis
Parenteral nutrition
Chemotherapy

30-40%

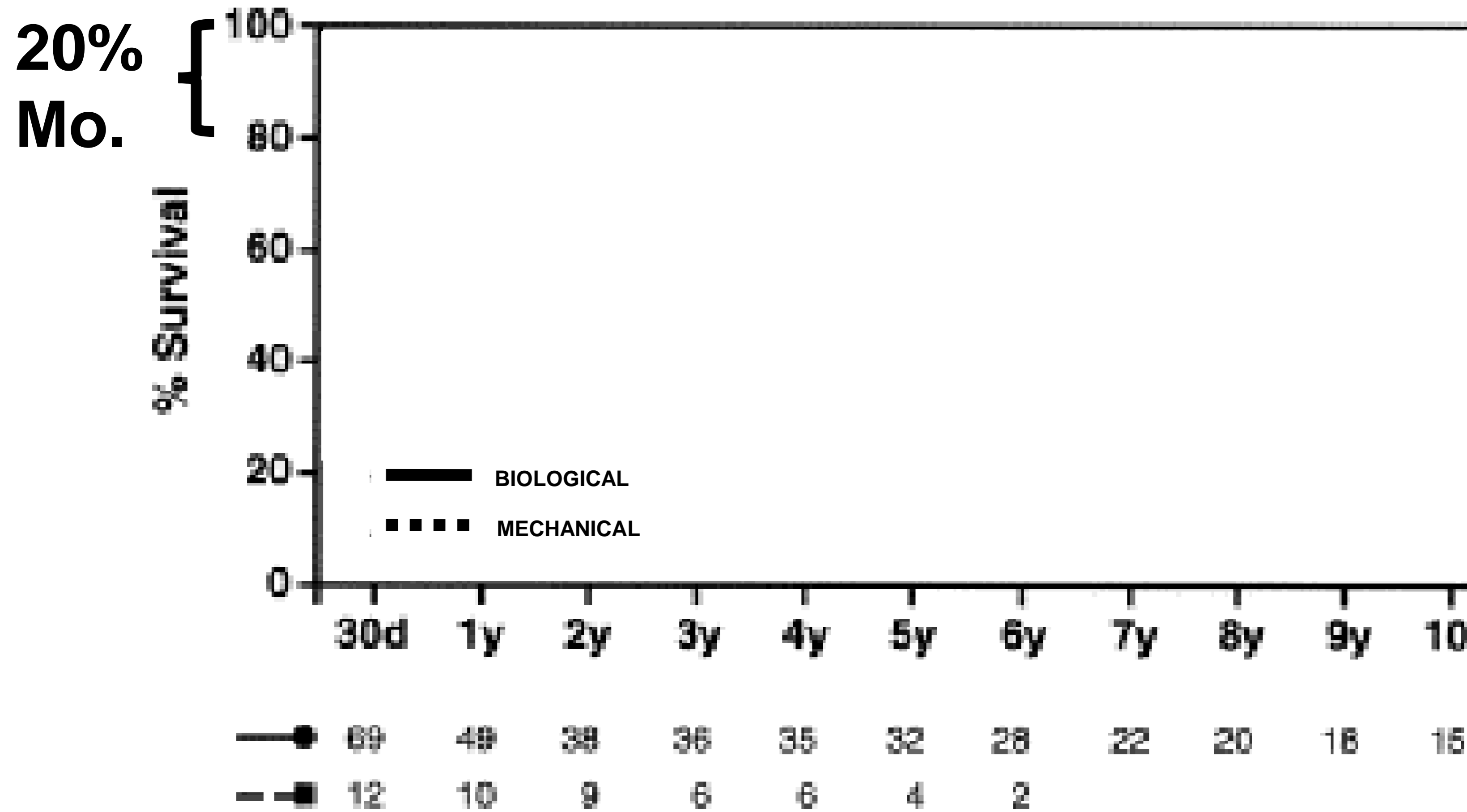
n=110/43

SURGICAL OPTIONS

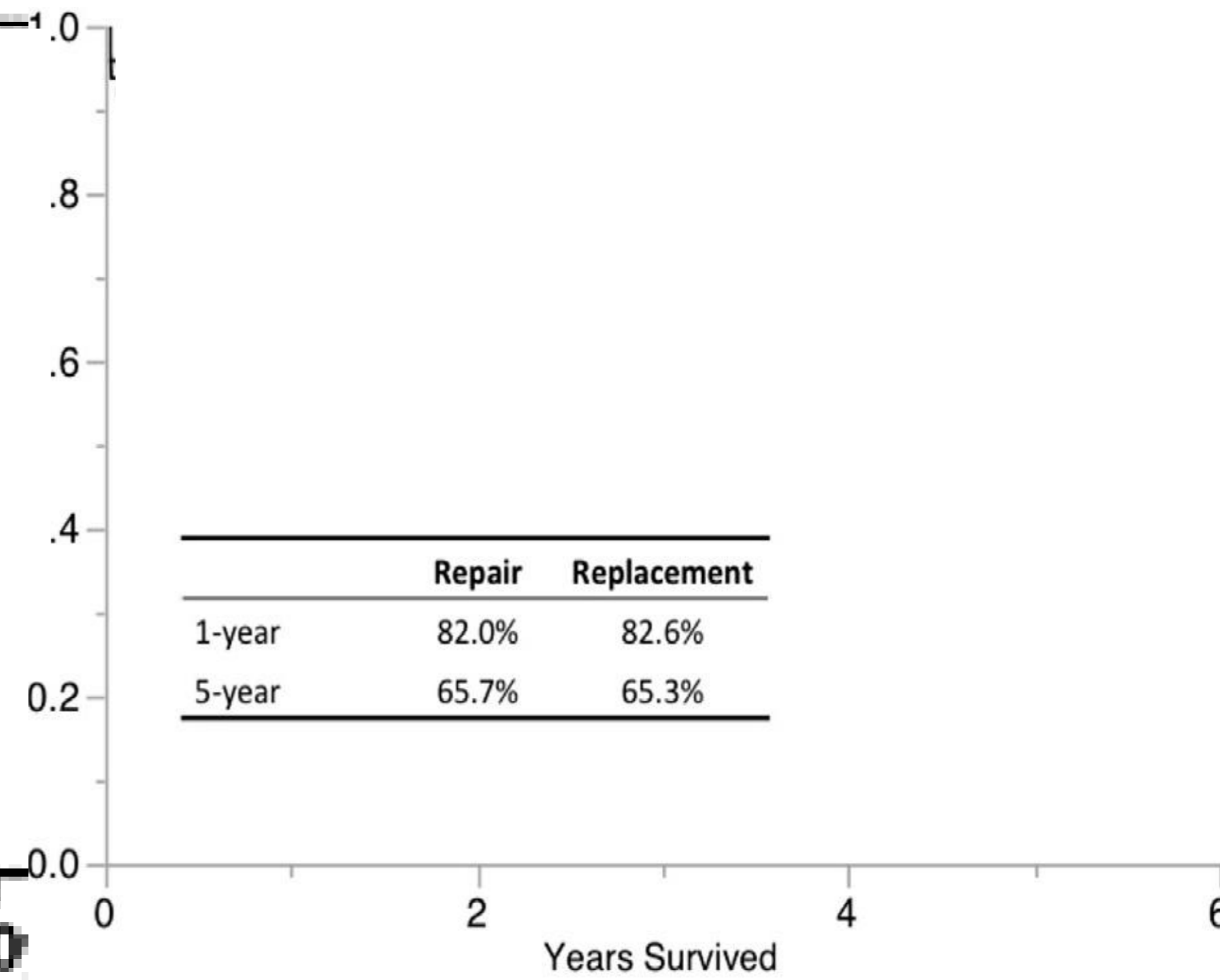


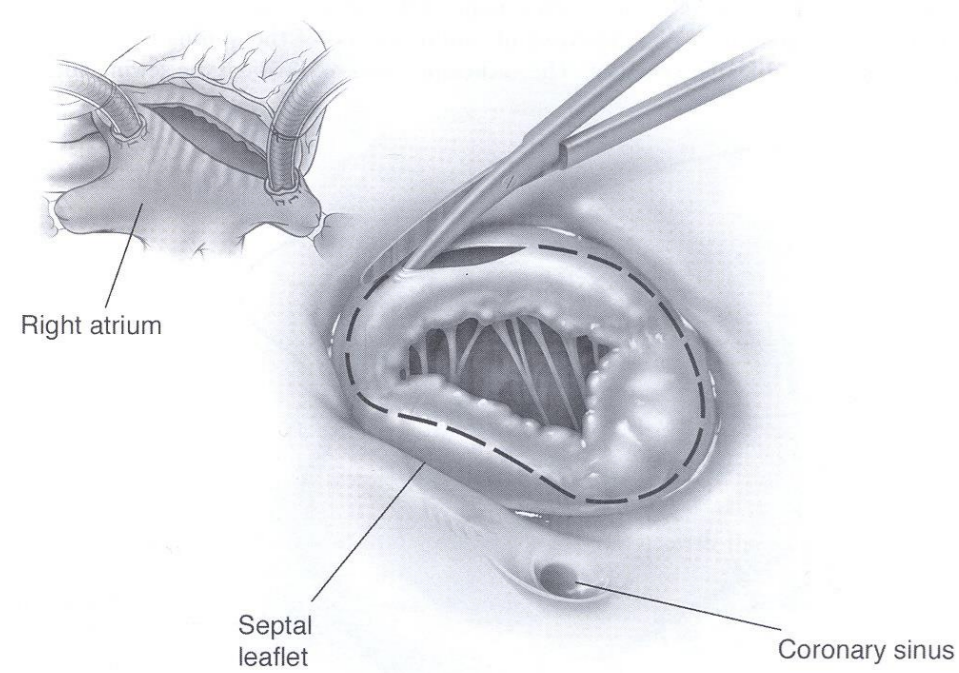
Survival Post - TV Replacement for Endocarditis

Biological and Mechanical Protheses

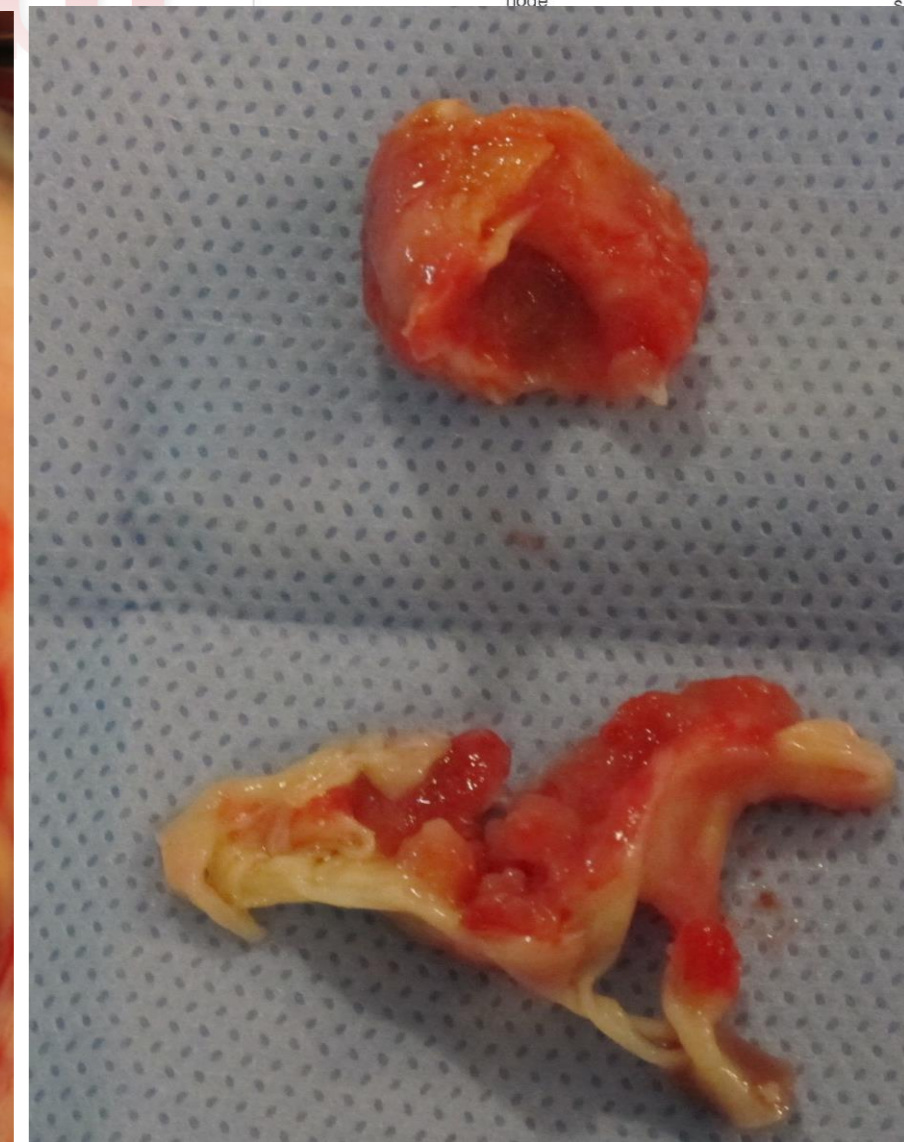
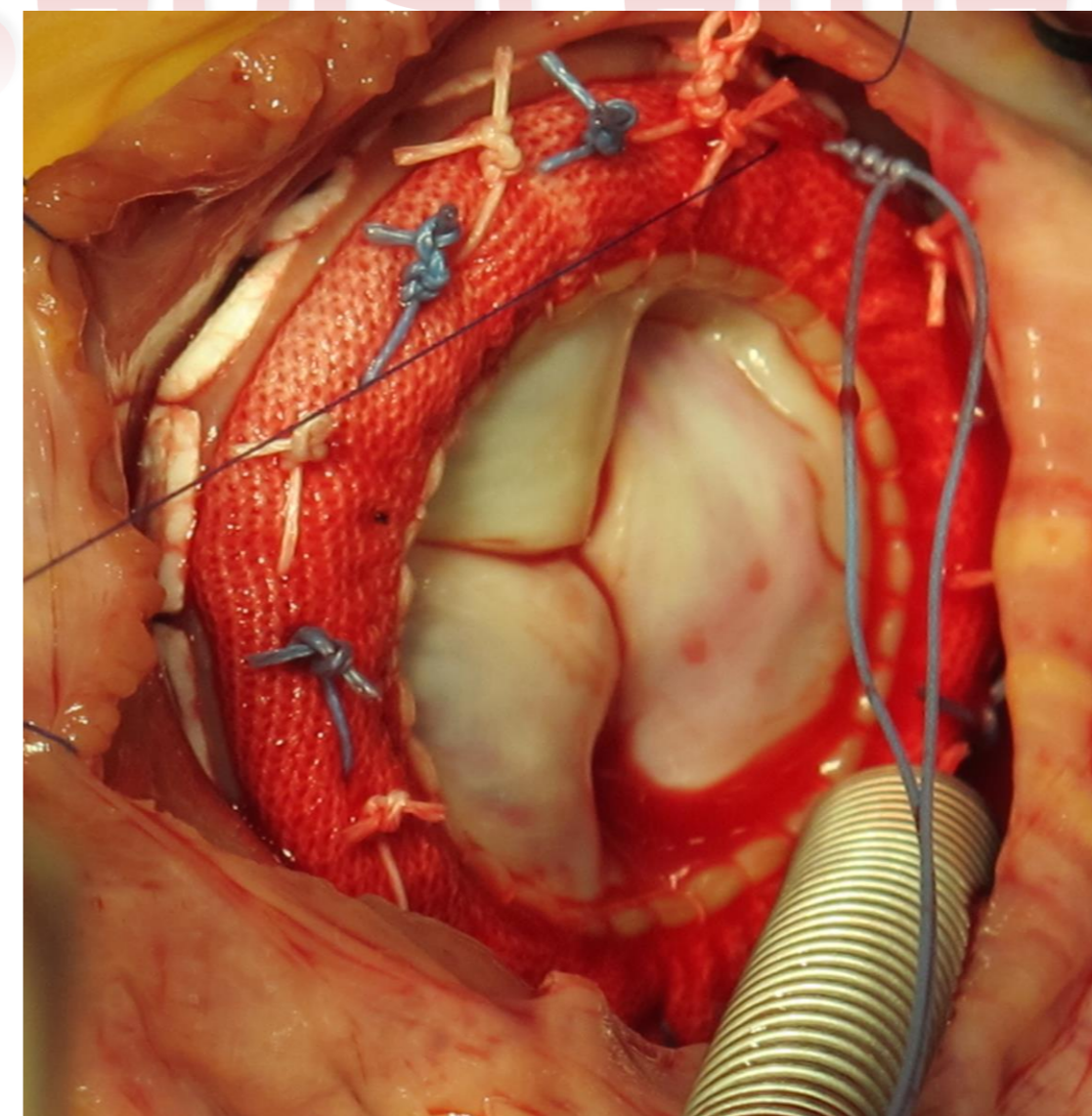
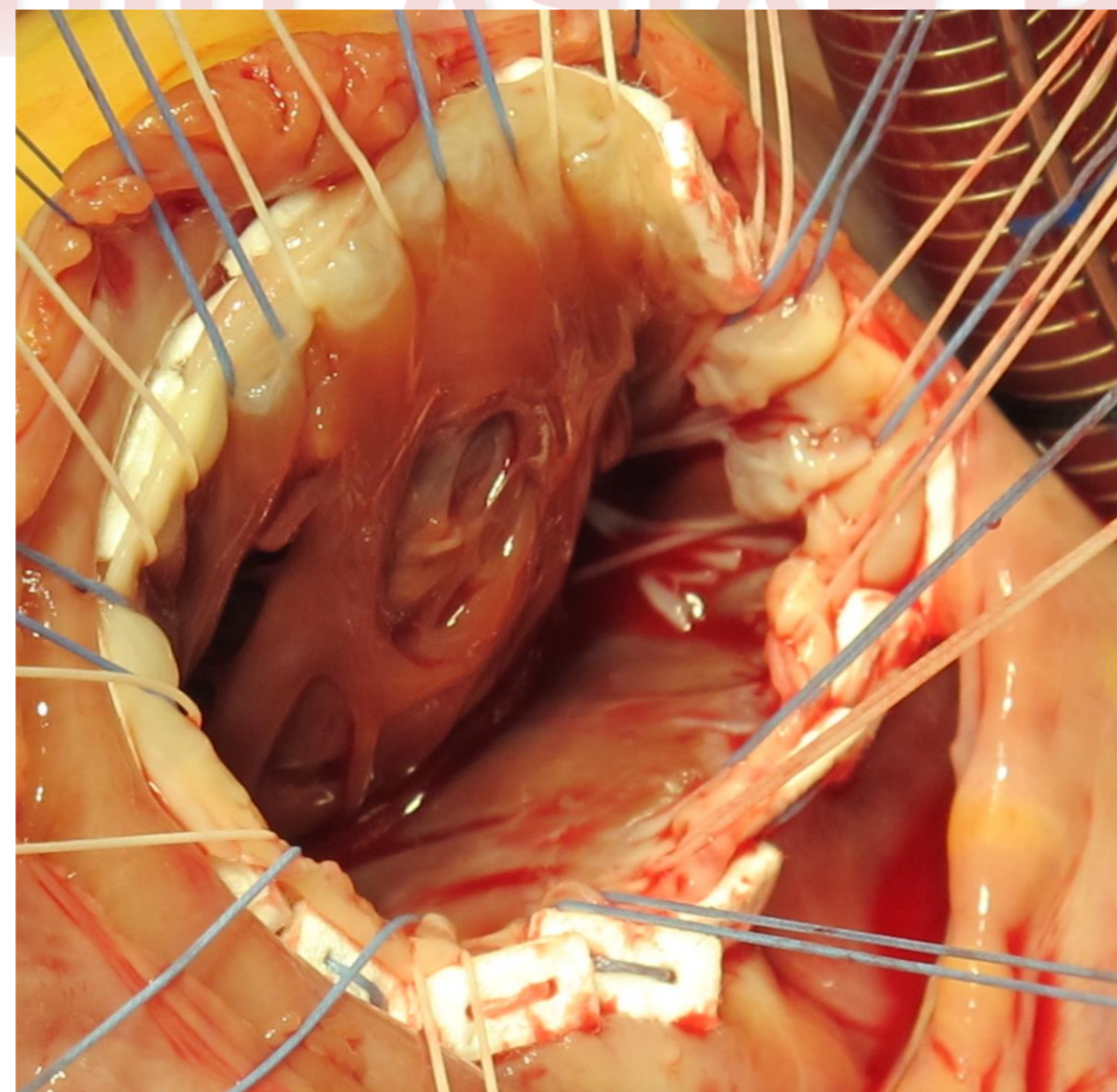
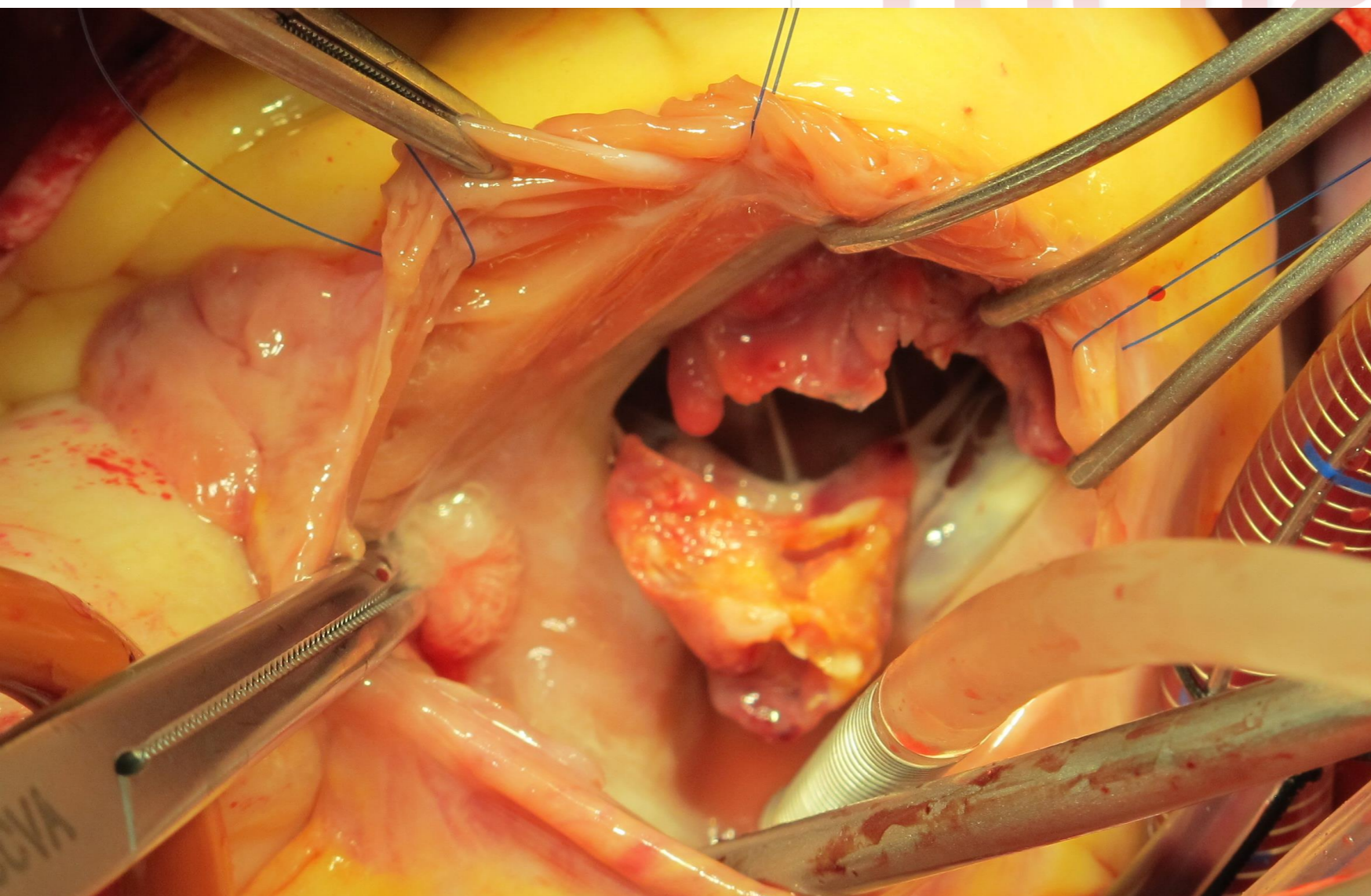
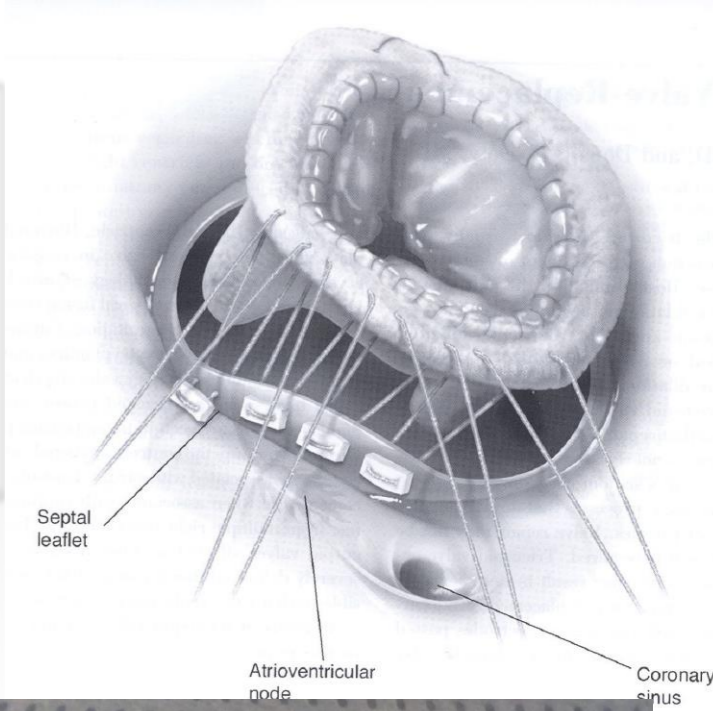


Repair vs Replacement Survival





Tricuspid Valve Replacement

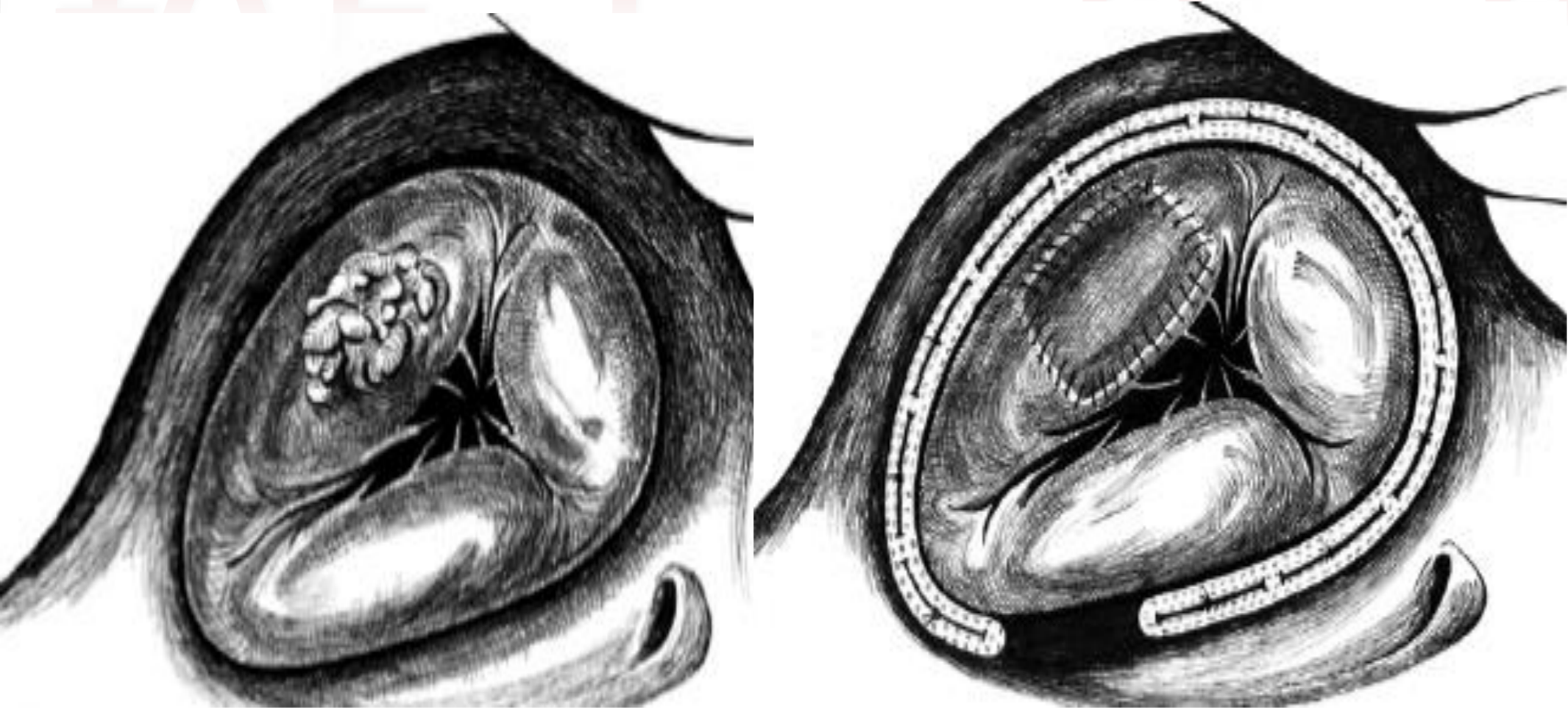


Decreased risk of recurrent TR

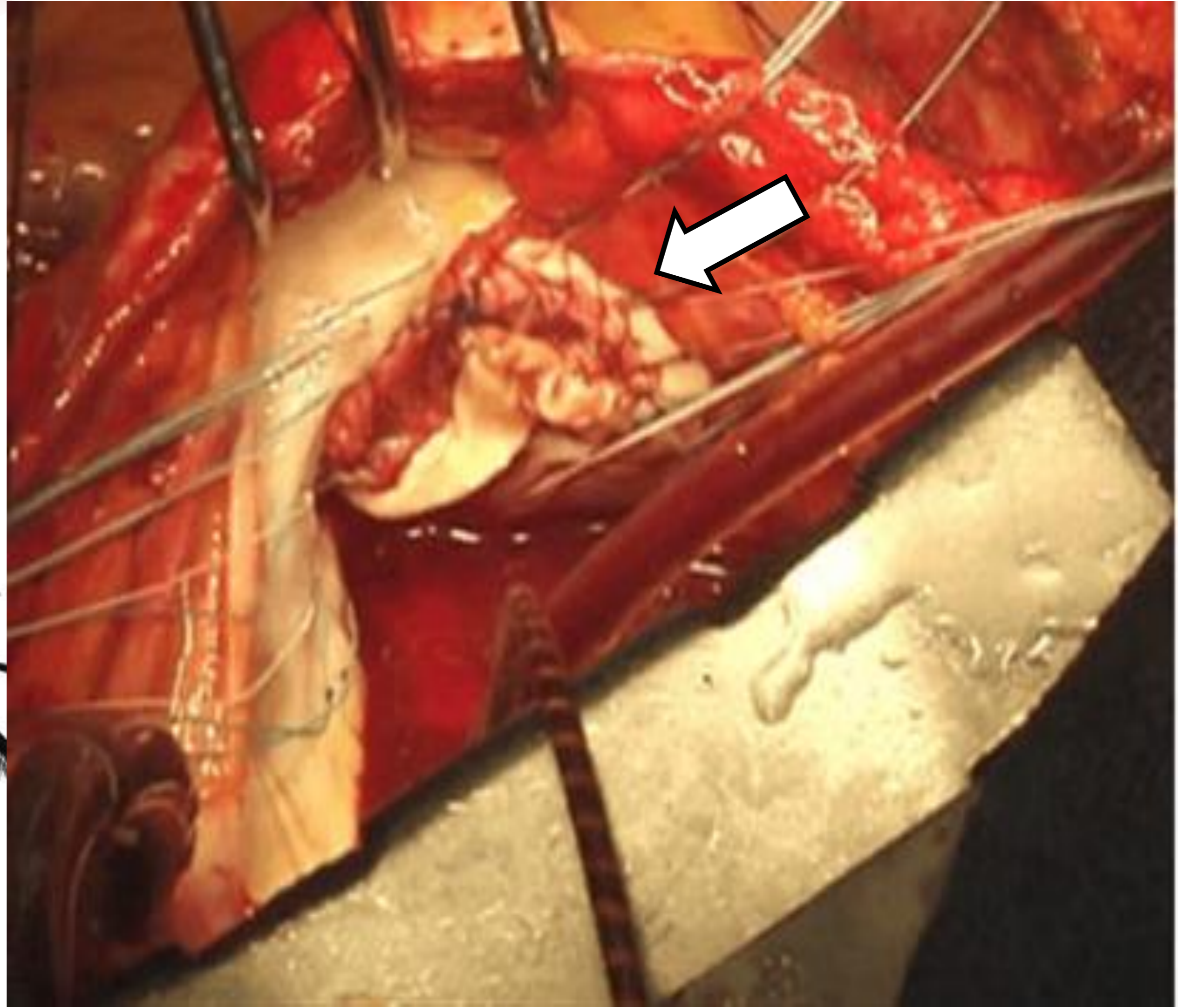
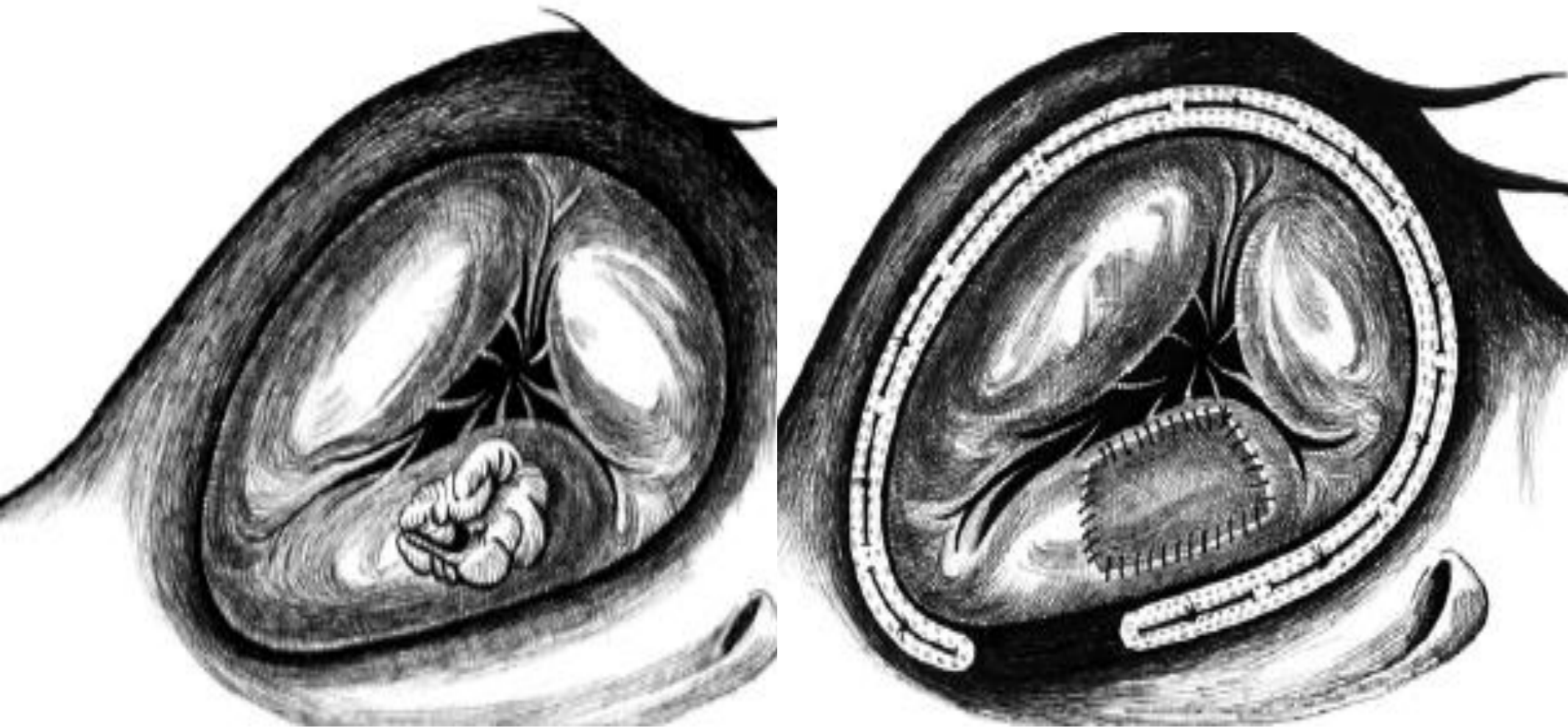
Increased risk of thromboembolic complications (especially mechanical)

TV Endocarditis: Reconstructive Techniques

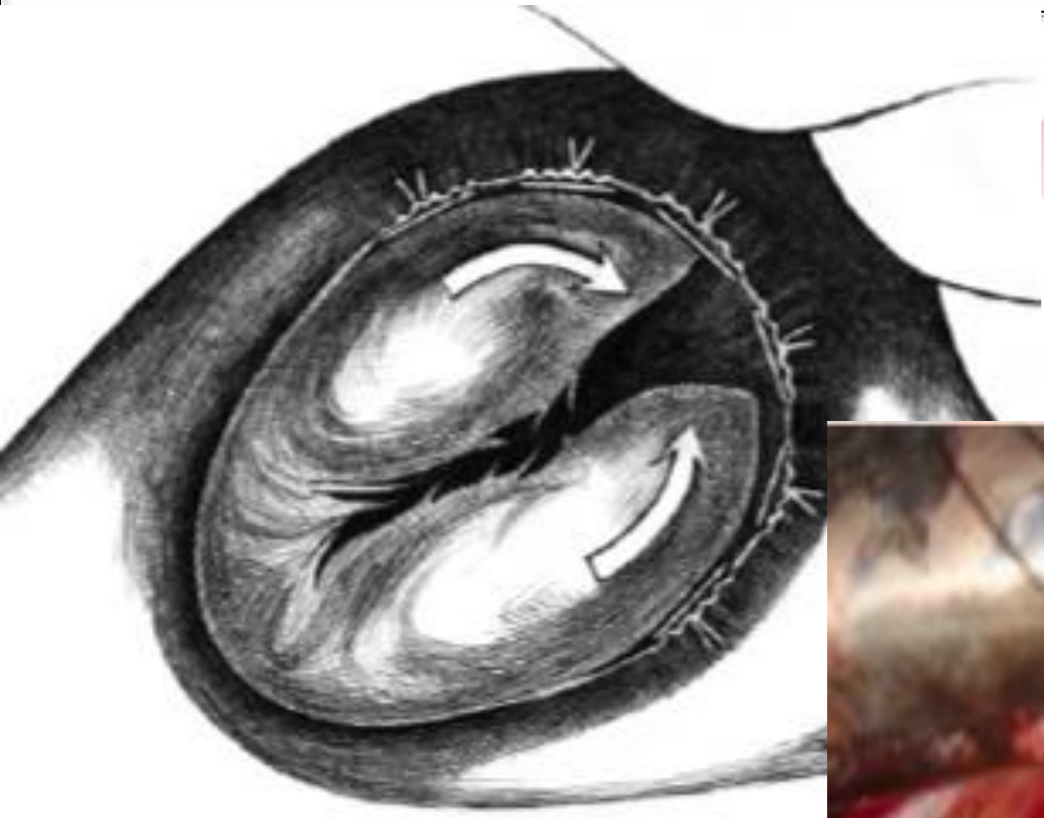TV Endocarditis: Reconstructive Techniques



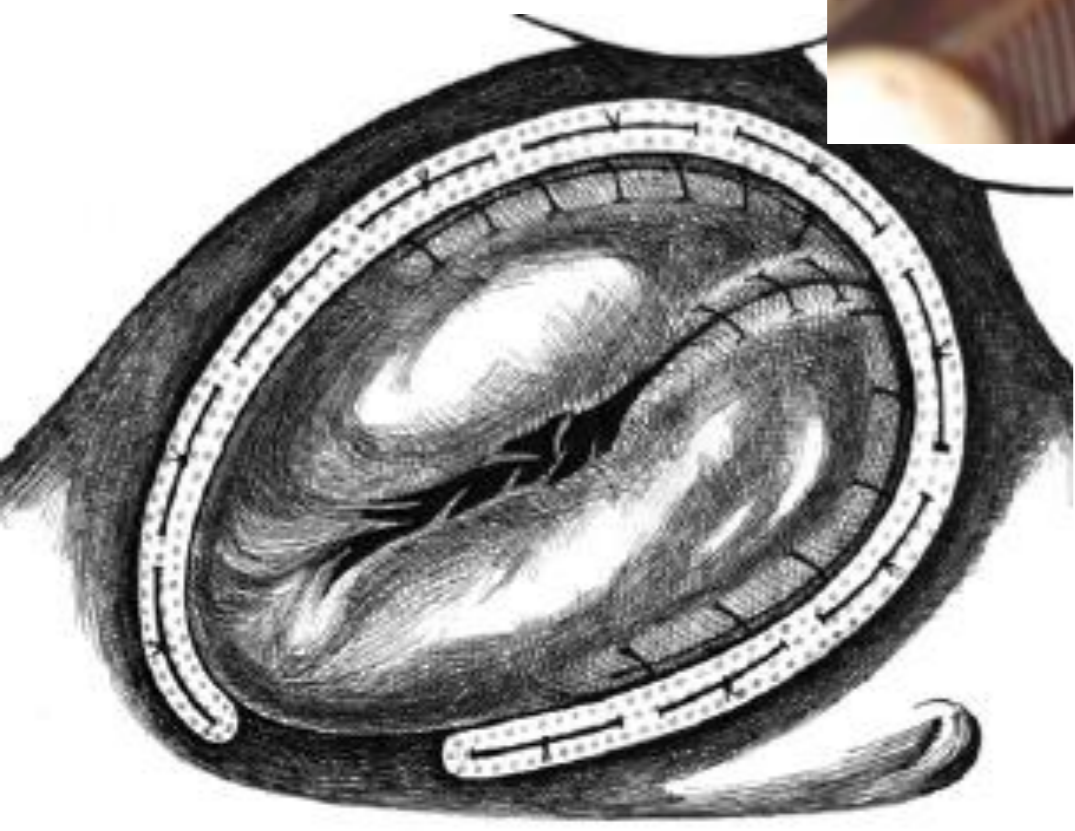
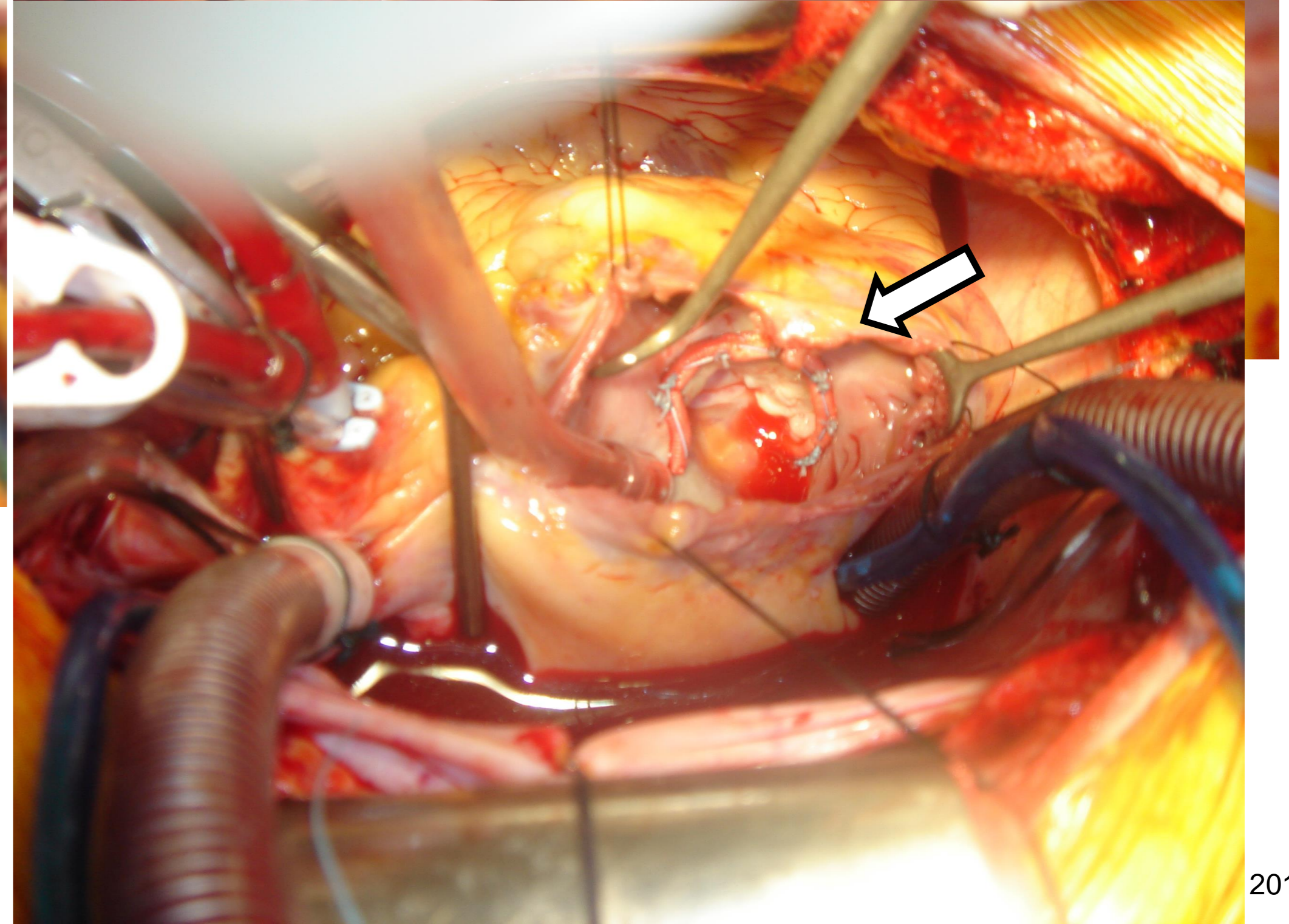
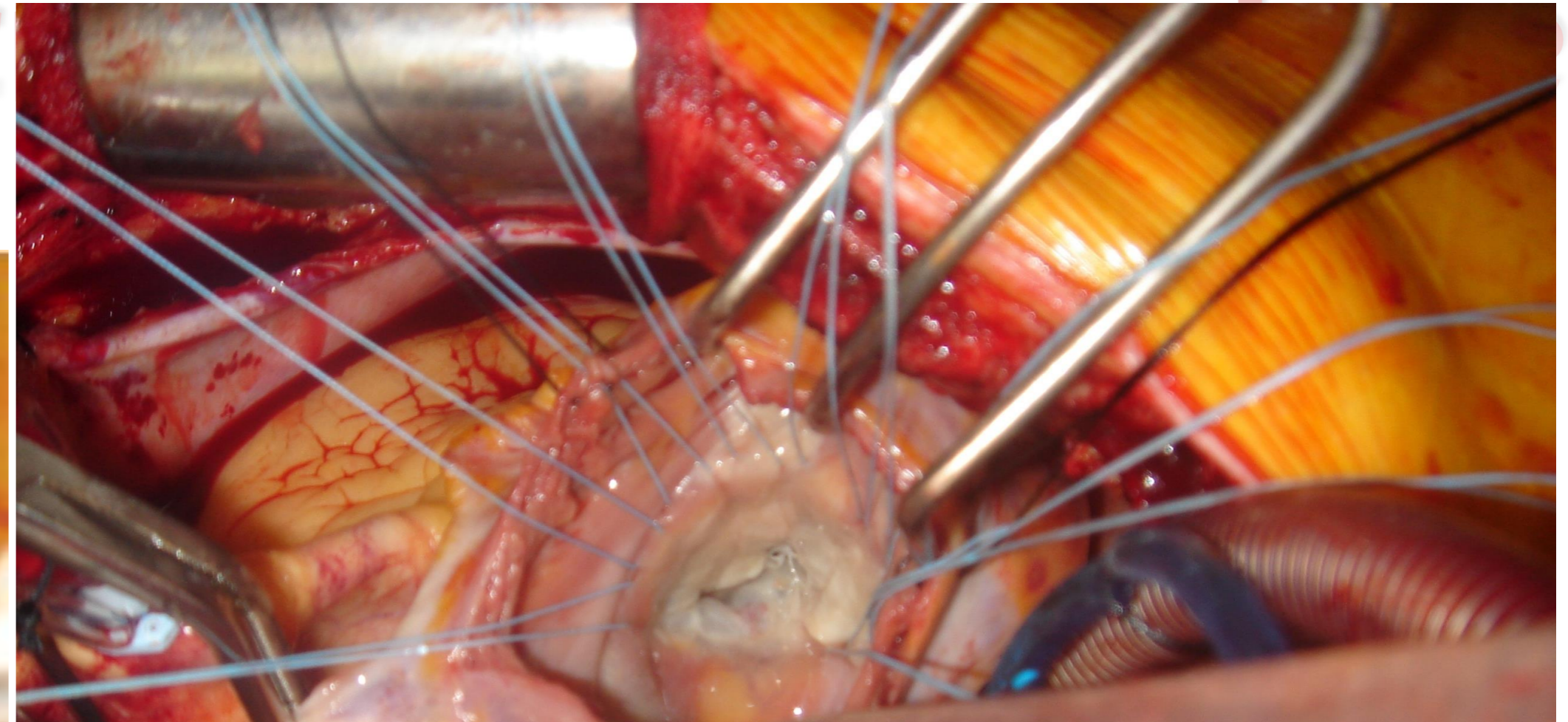
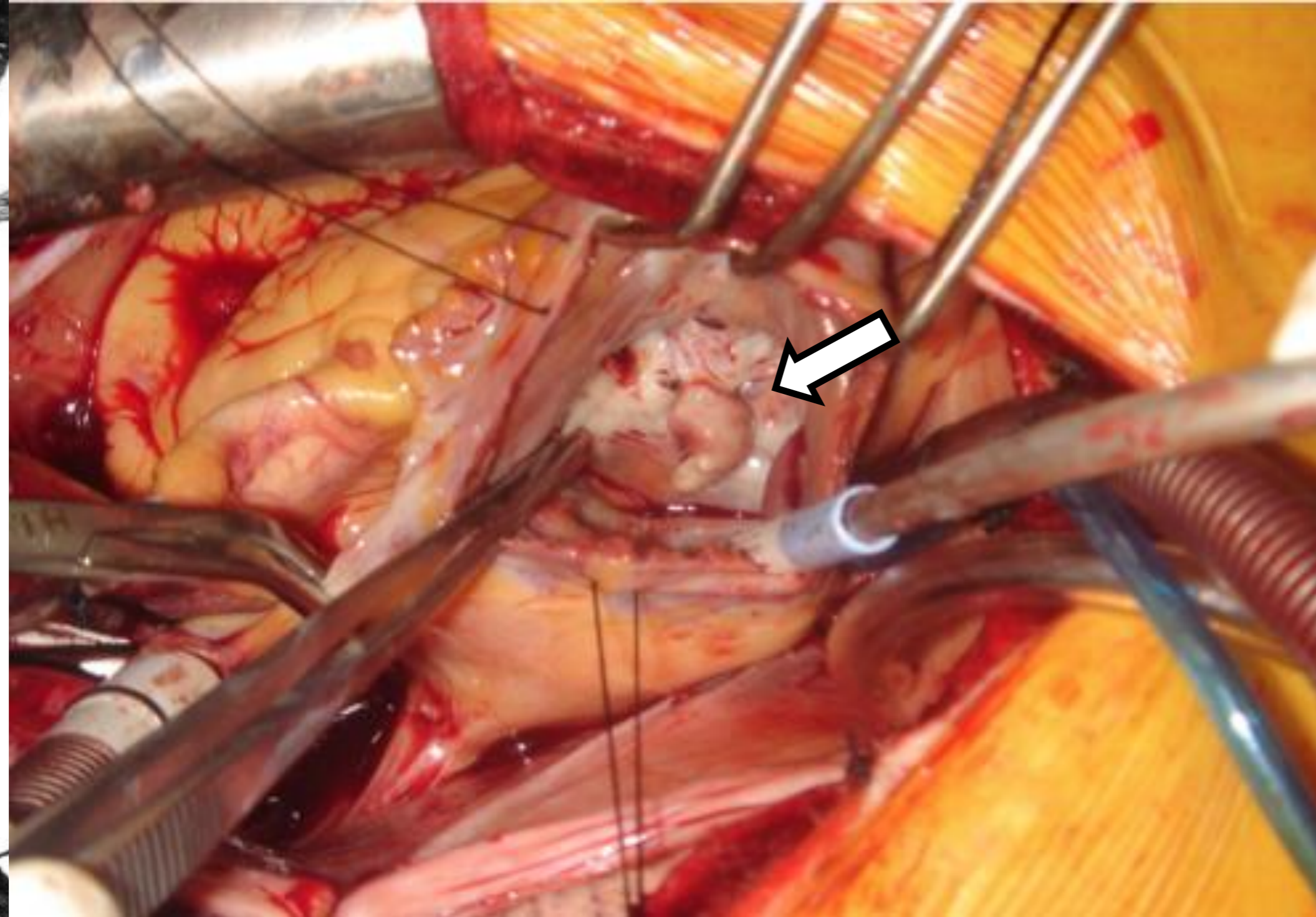
PERICARDIAL PATCH REPAIR



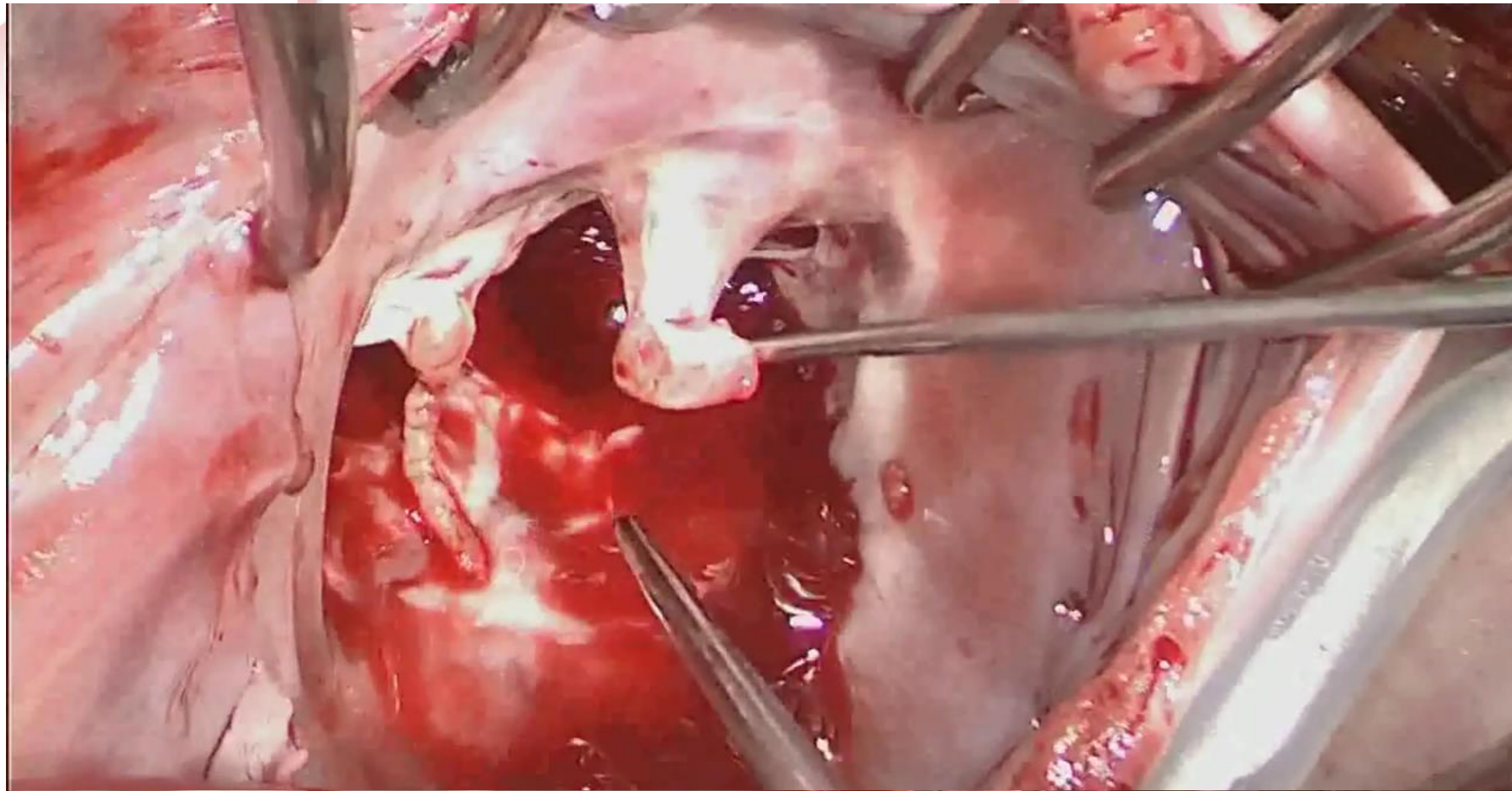
TV Endocarditis: Reconstructive Techniques



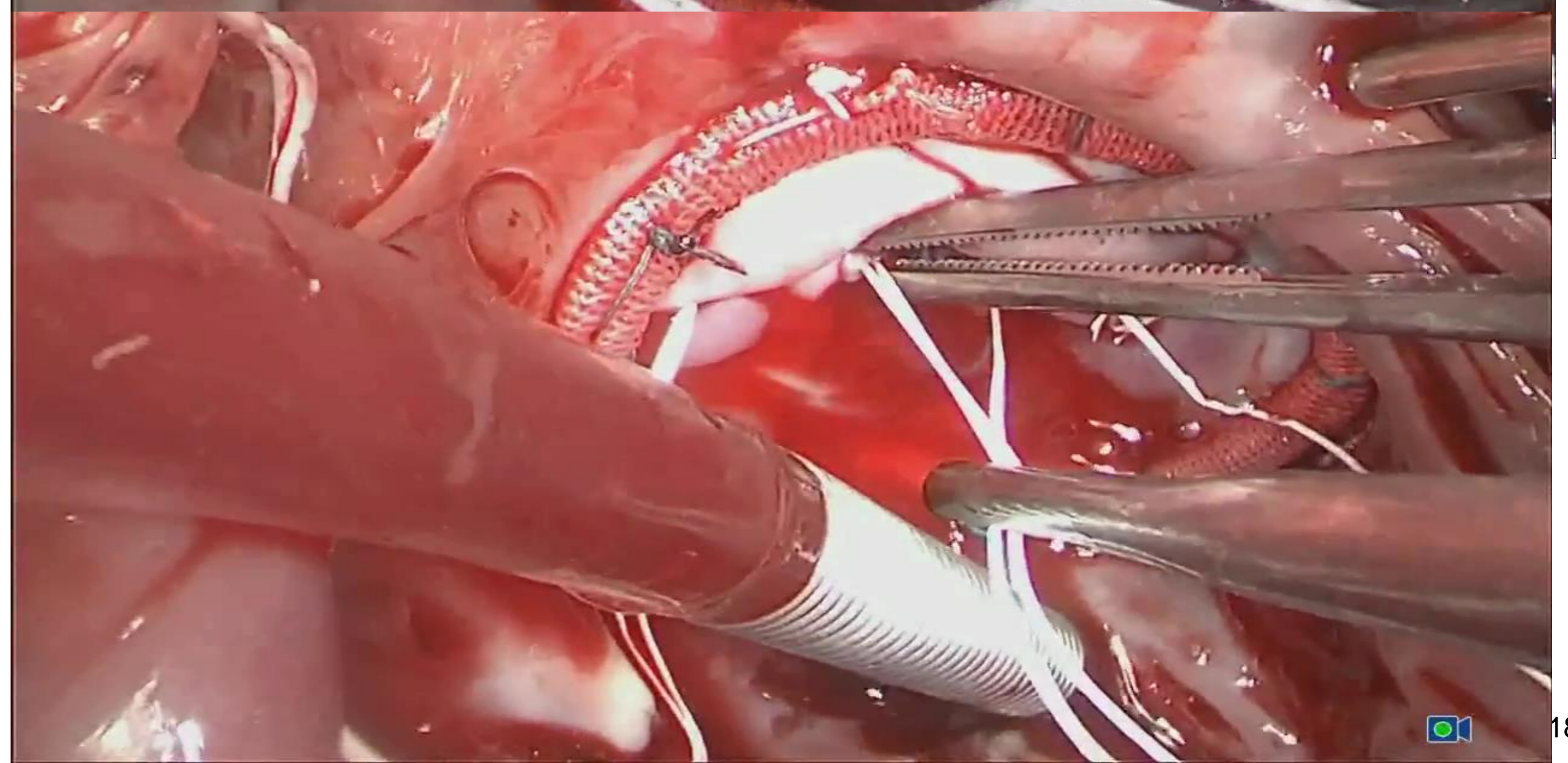
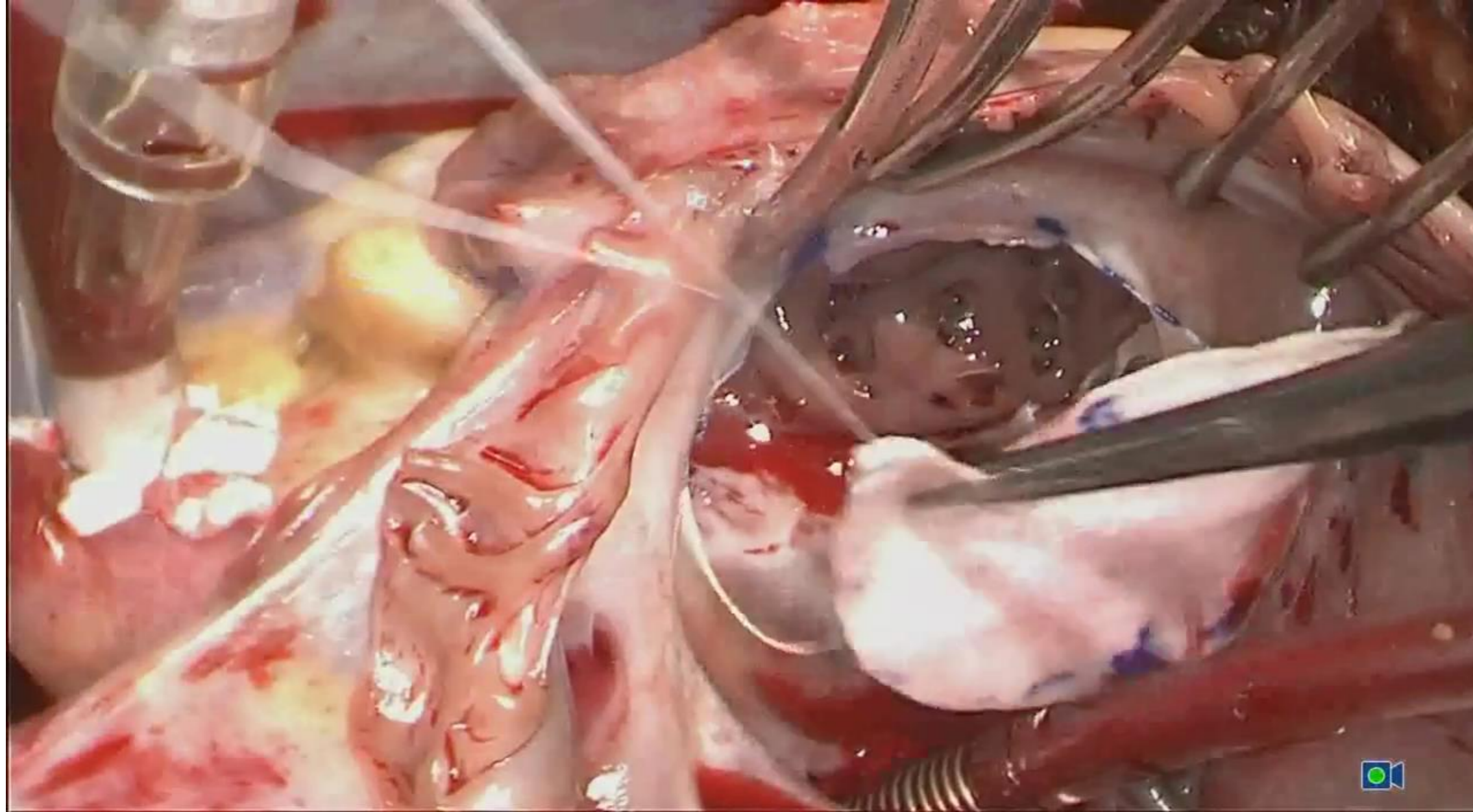
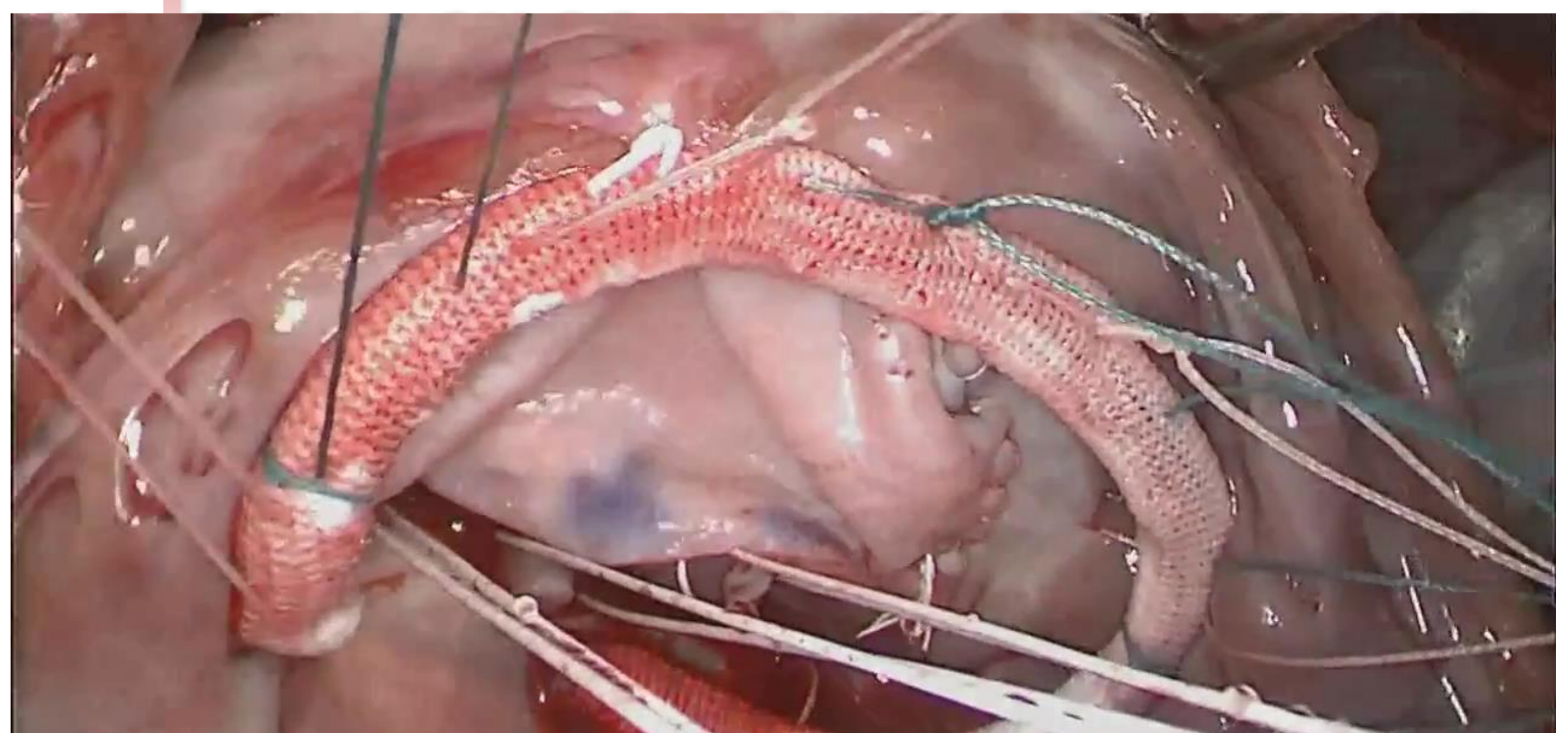
carditis: Reconst



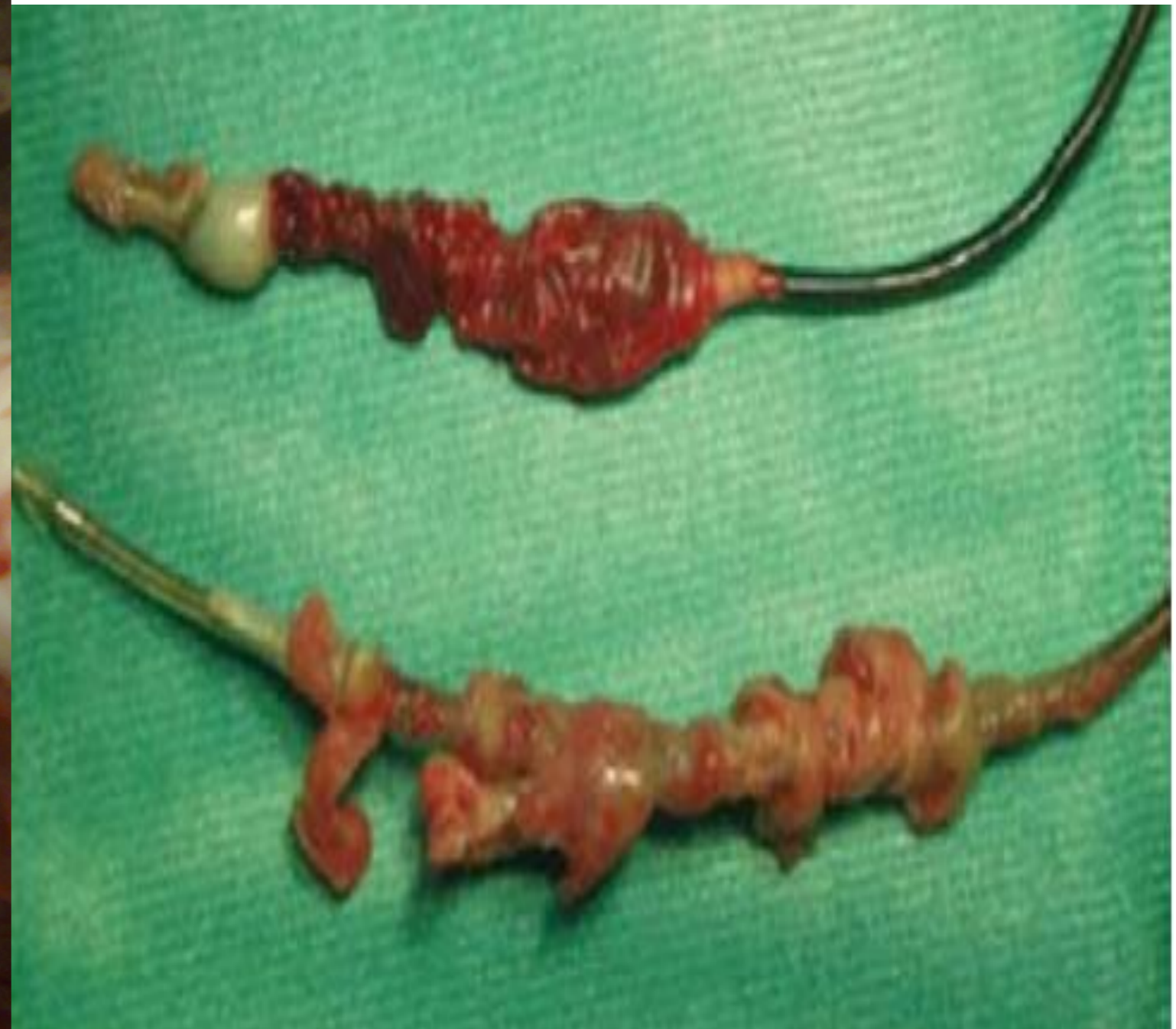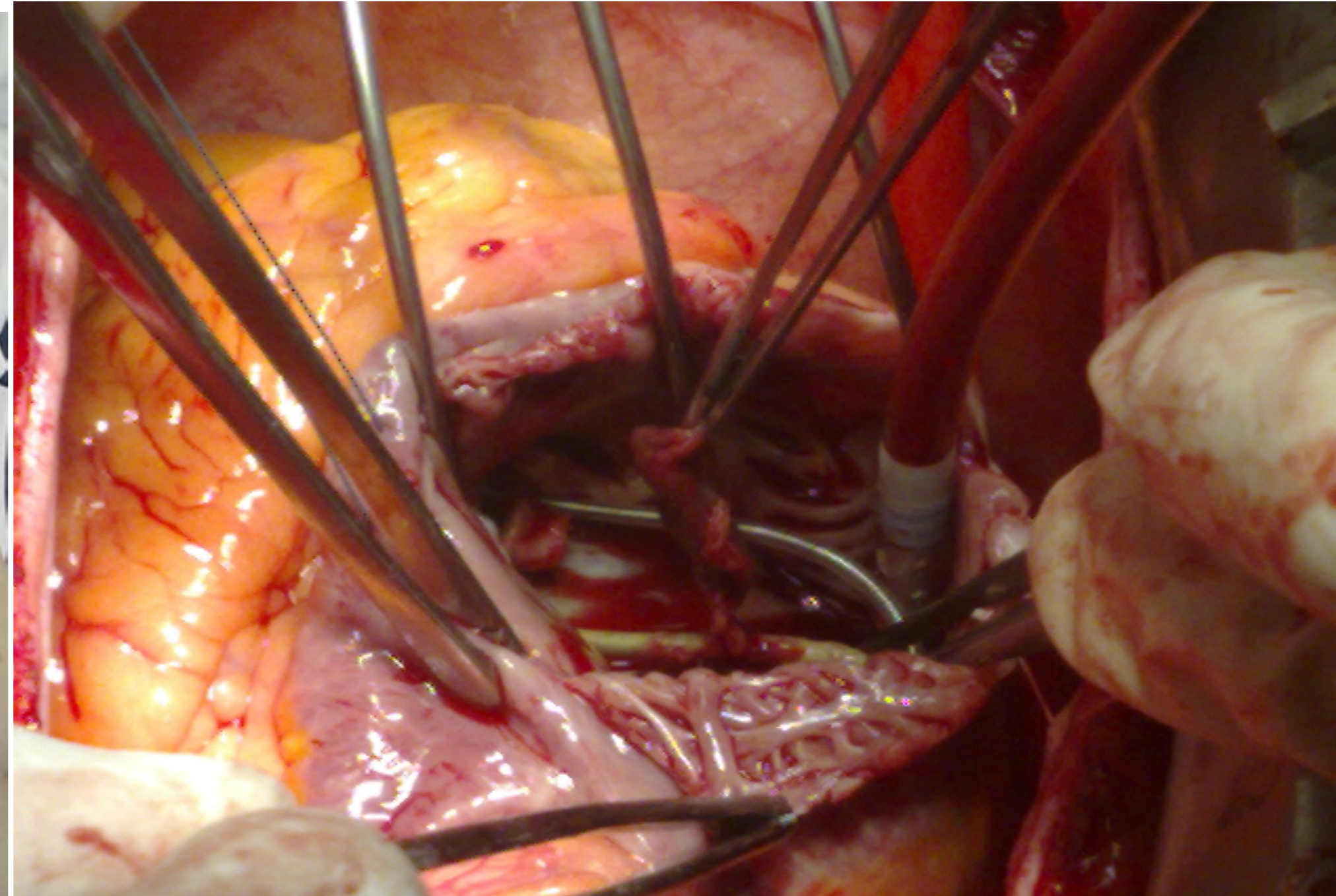
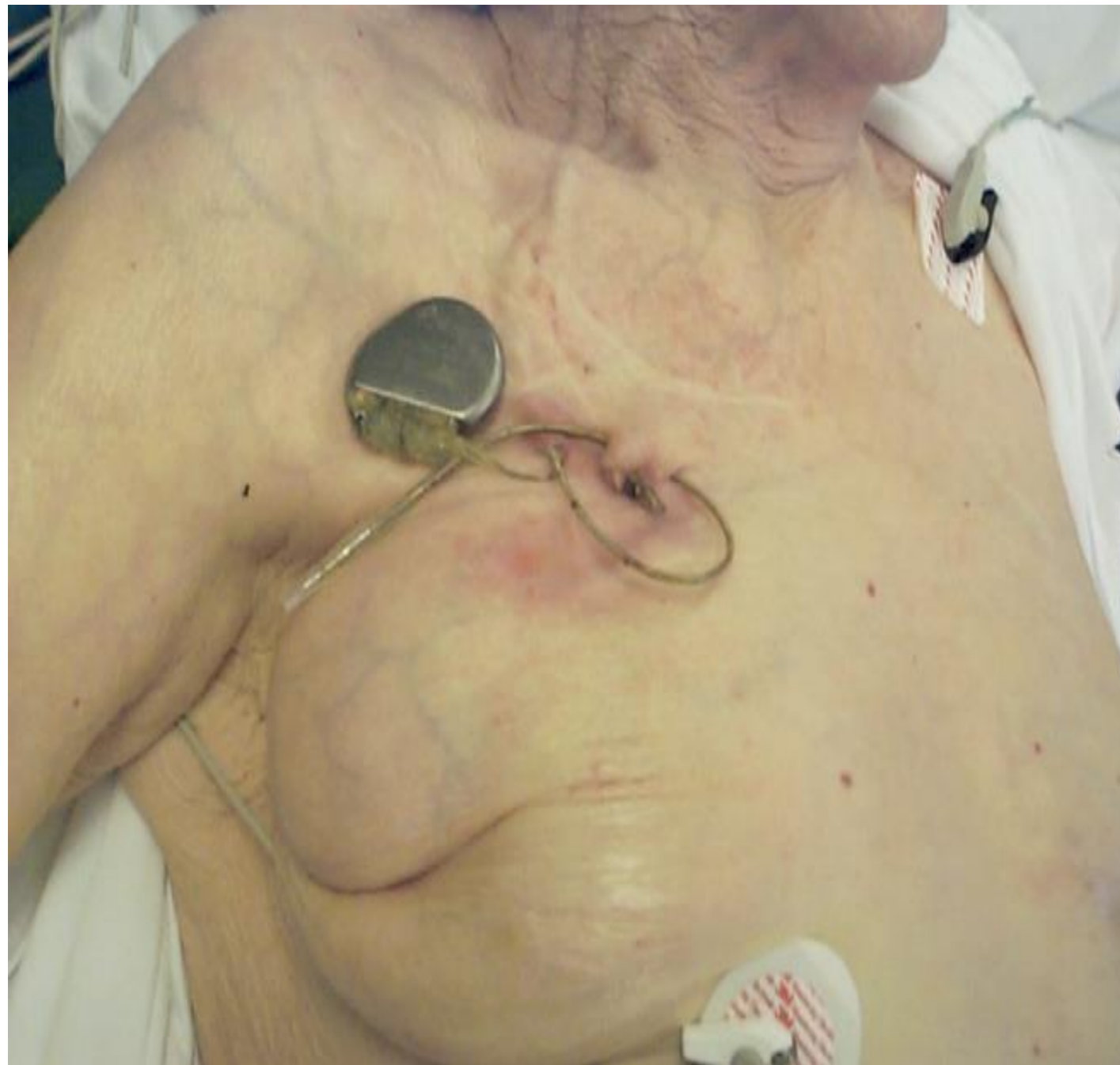
Complex tricuspid valve repair after endocarditis



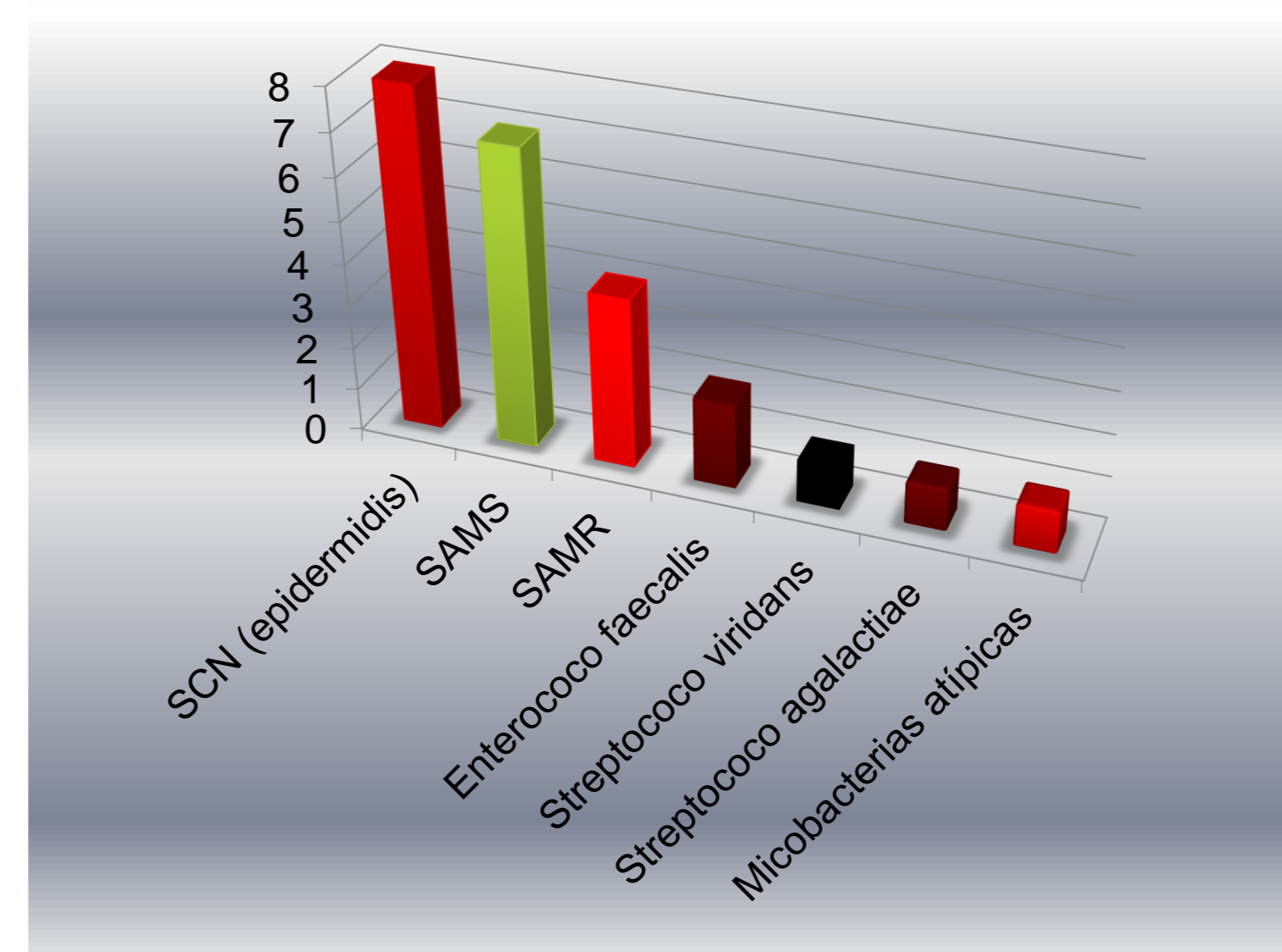
6



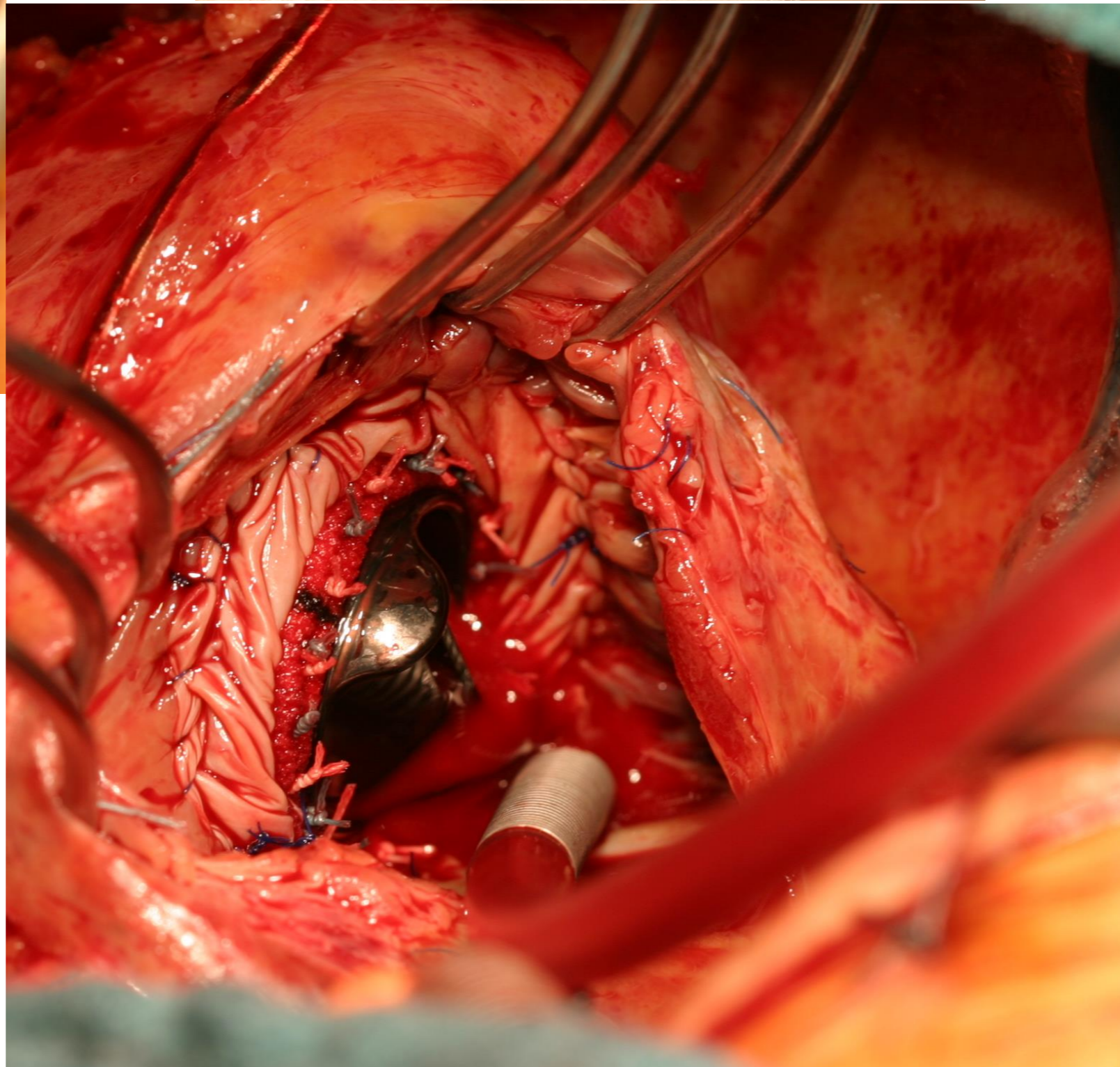
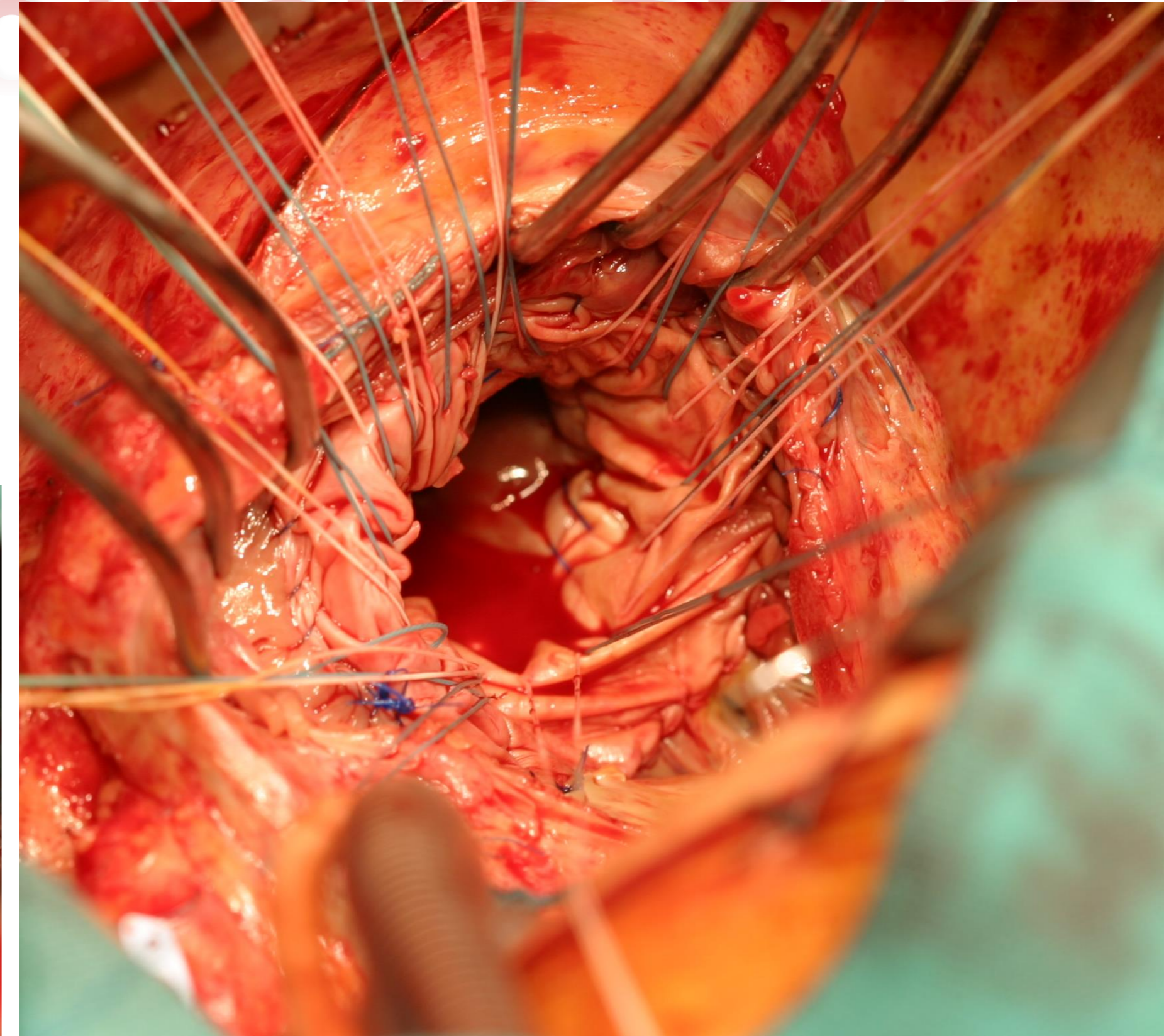
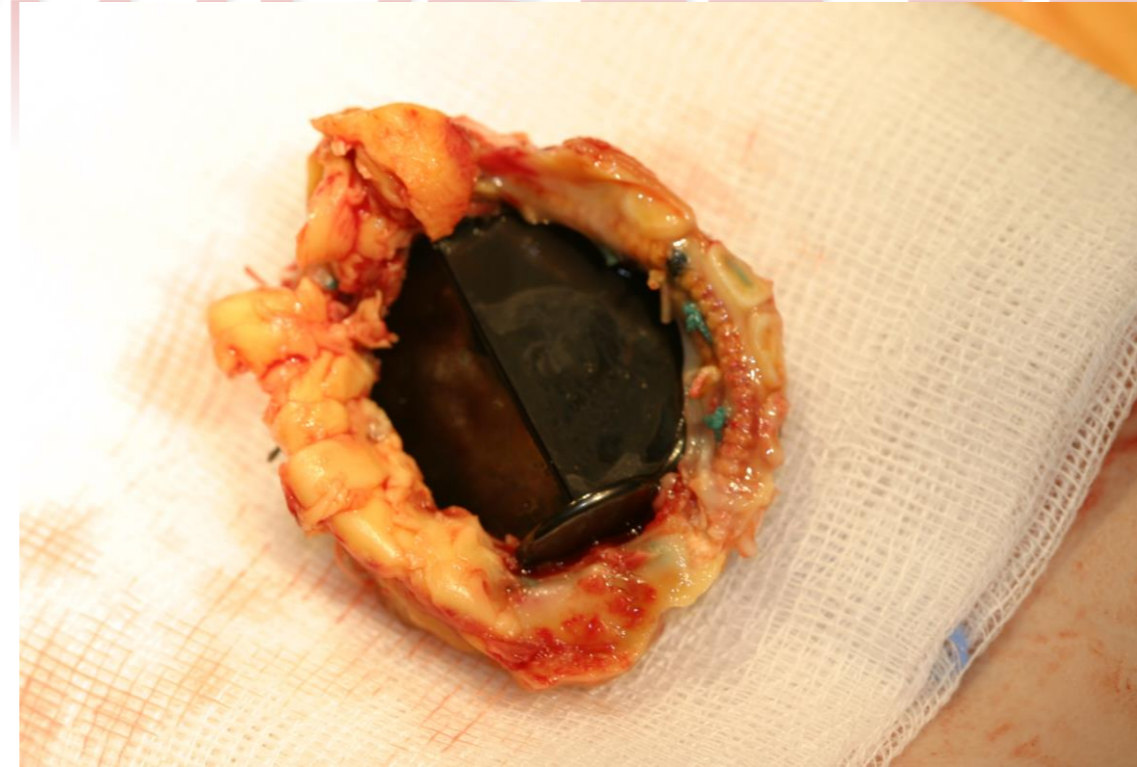
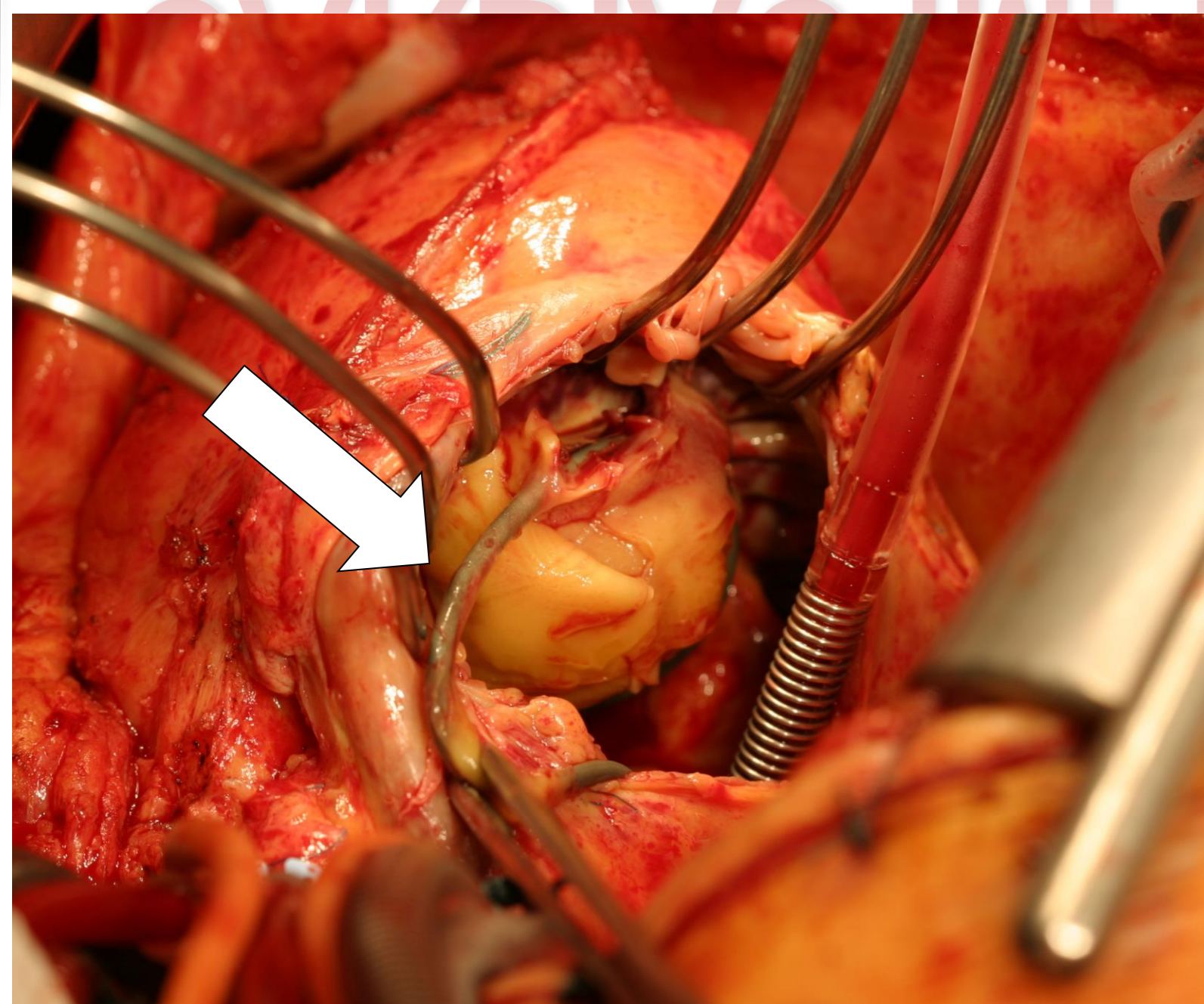
CARDIAC IMPLANTABLE ELECTRONIC DEVICE



- January 2010 a October 2018 → 2423
- n= 43

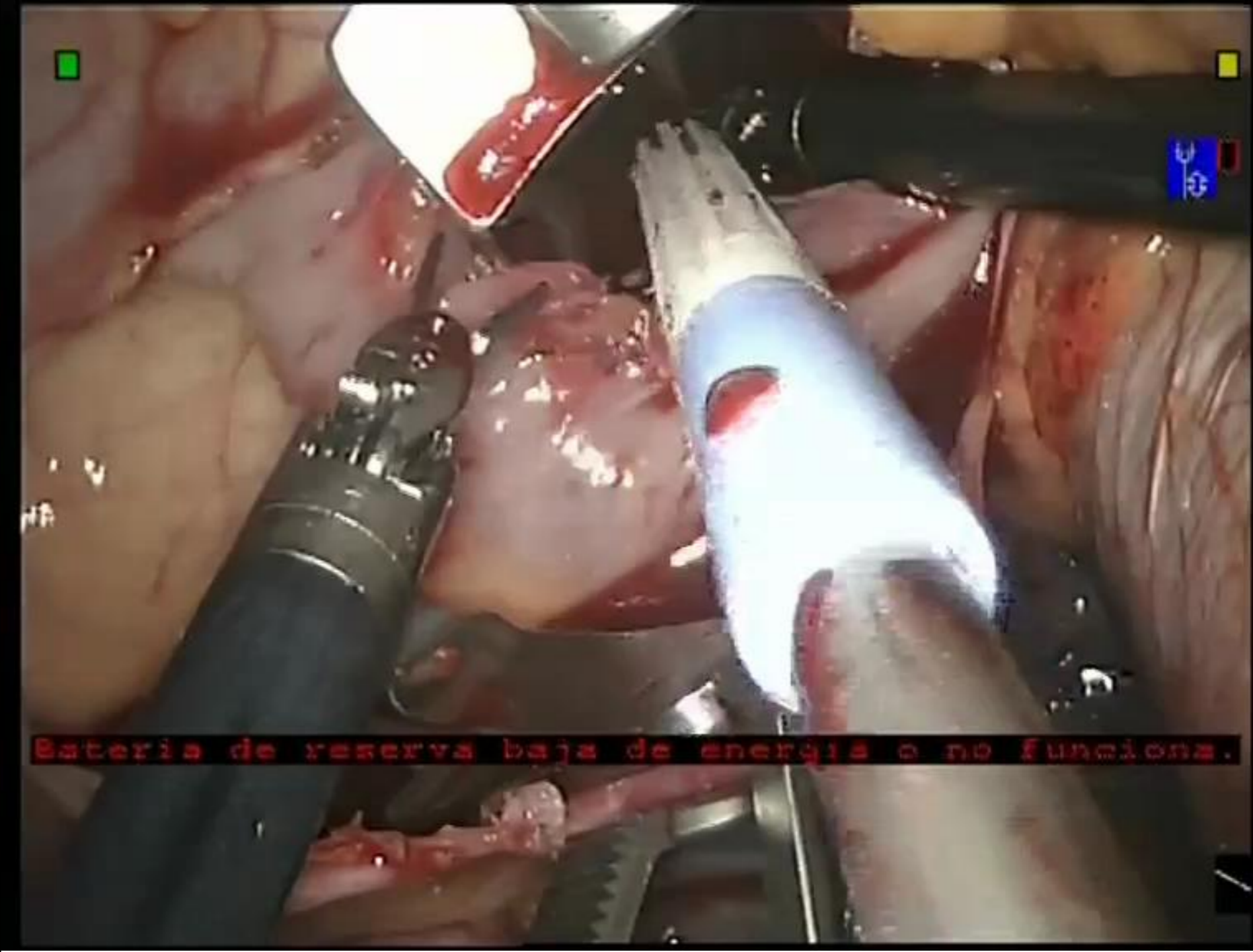
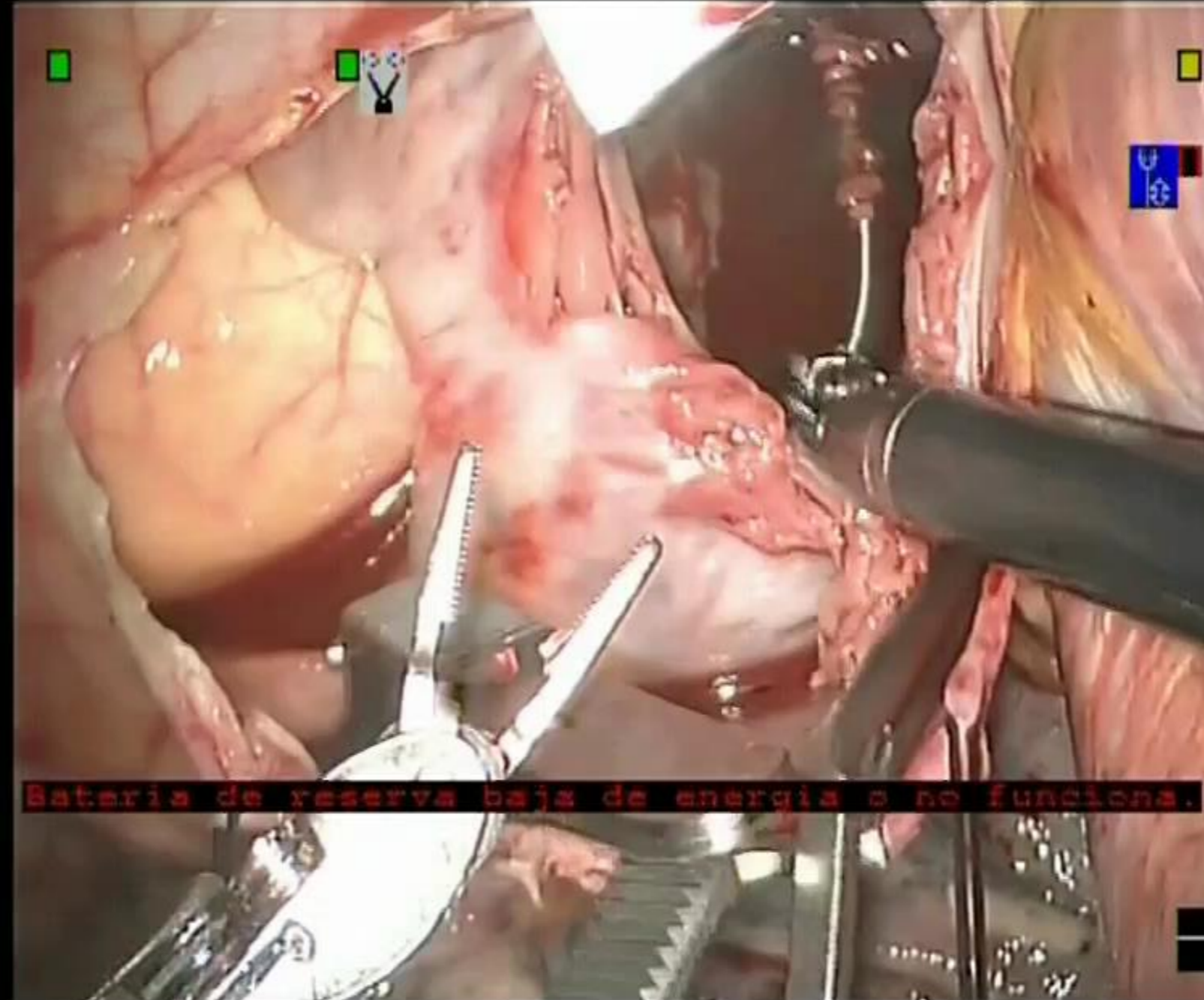
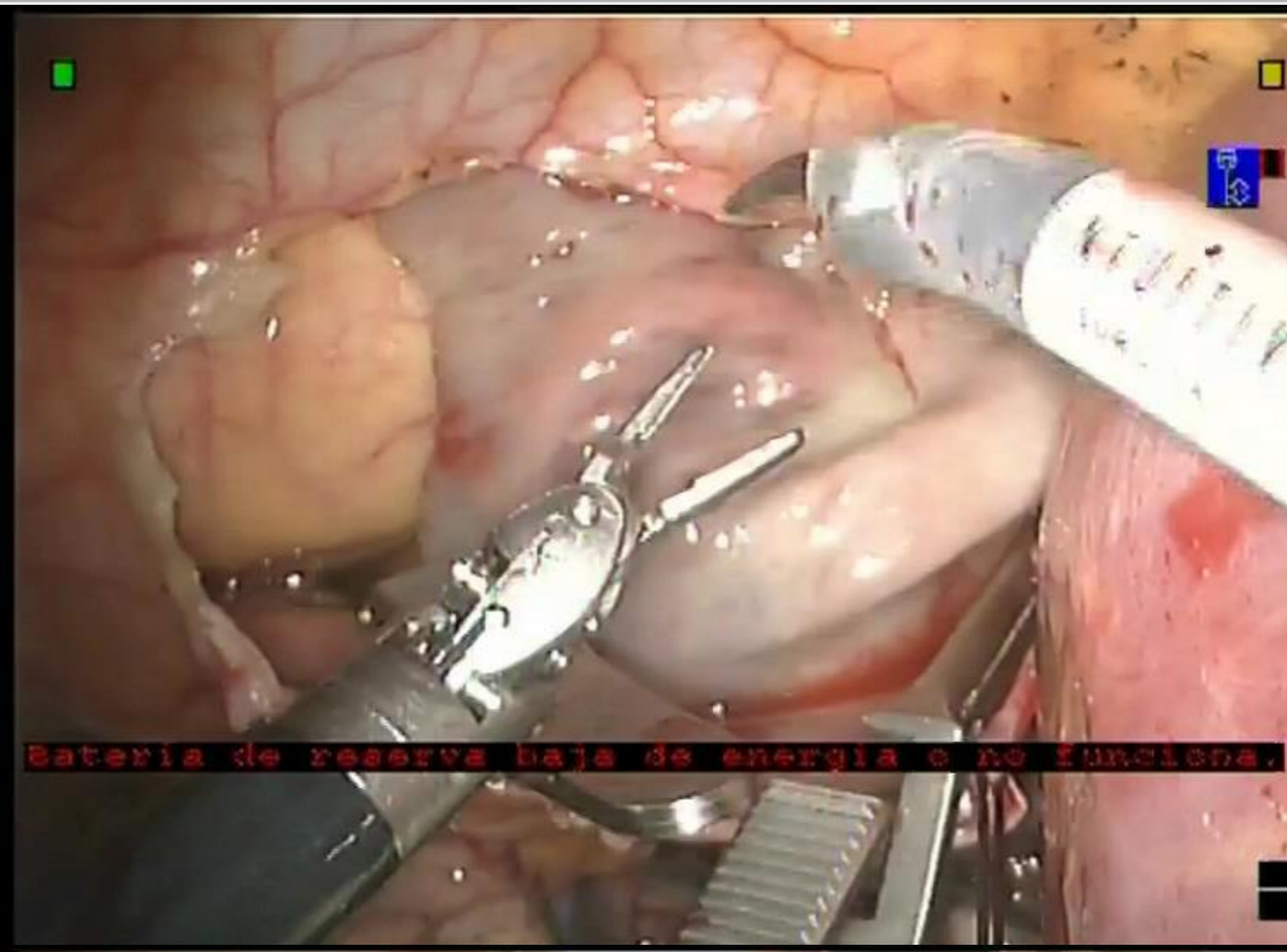
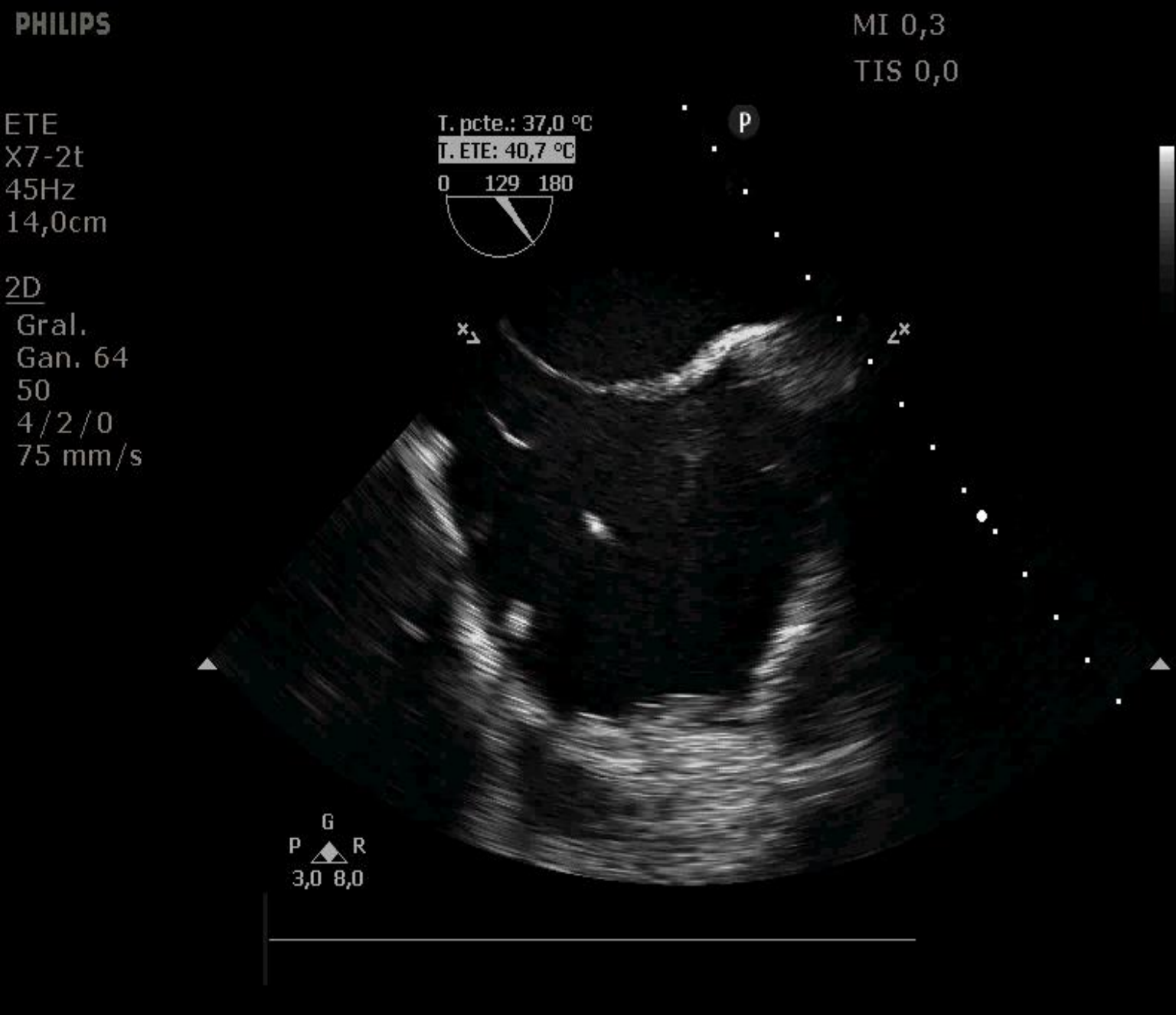
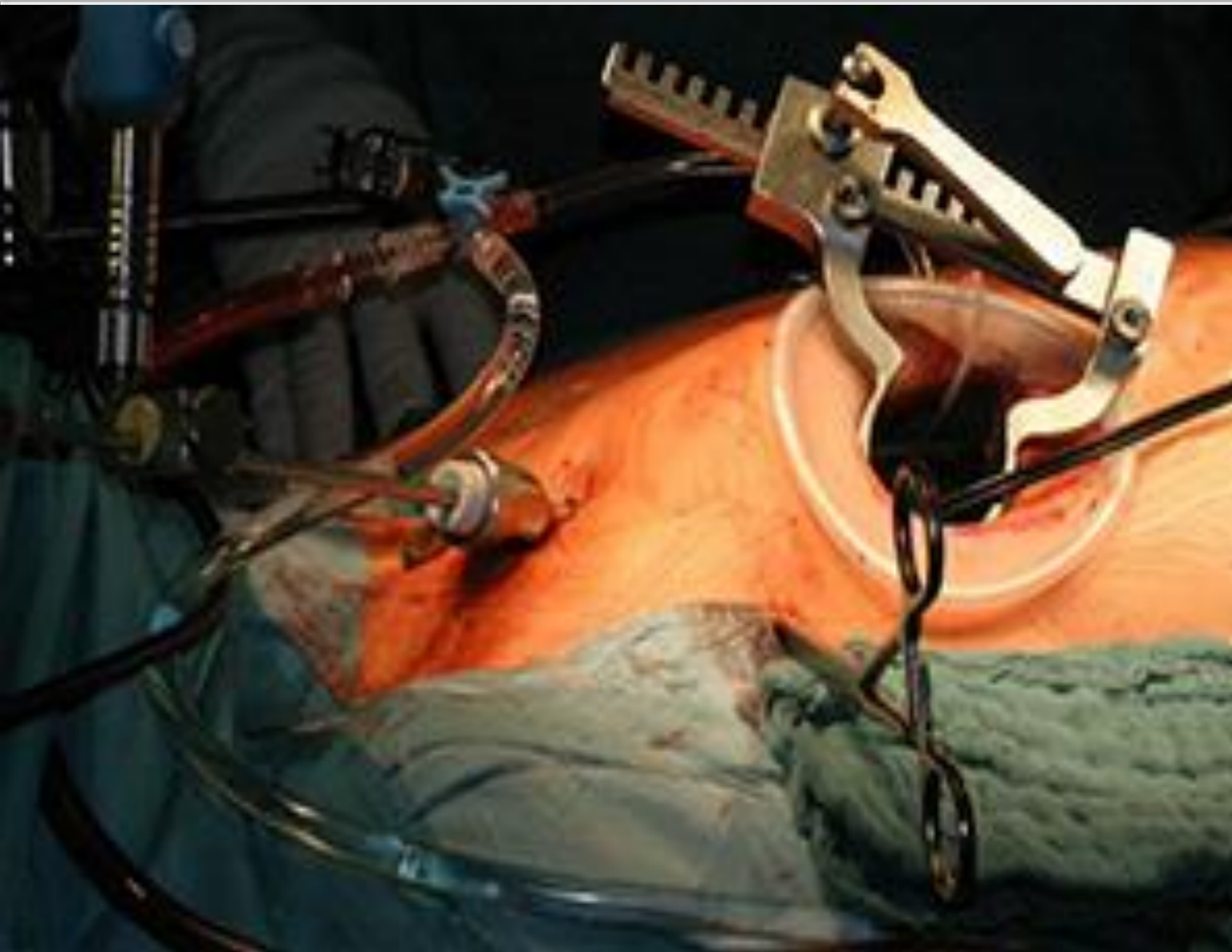


CARDIAC IMPLANTABLE ELECTRONIC DEVICE



Complex
Tricuspid Valve
REDO

SIMPLE EXCISION OF THE VEGETATION



STS/EACTS Latin America Cardiovascular Surgery Conference

November 15-17, 2018

Hilton Cartagena | Cartagena, Colombia



The Society
of Thoracic
Surgeons



EACTS
European Association for Cardio-Thoracic Surgery

THANK YOU

Dr. Vadim Kotowicz
Chief of Cardiovascular Service
Hospital Italiano de Buenos Aires
vadim.kotowicz@hospitalitaliano.org.ar