

STS/EACTS Latin America Cardiovascular Surgery Conference

November 15-17, 2018

Hilton Cartagena | Cartagena, Colombia

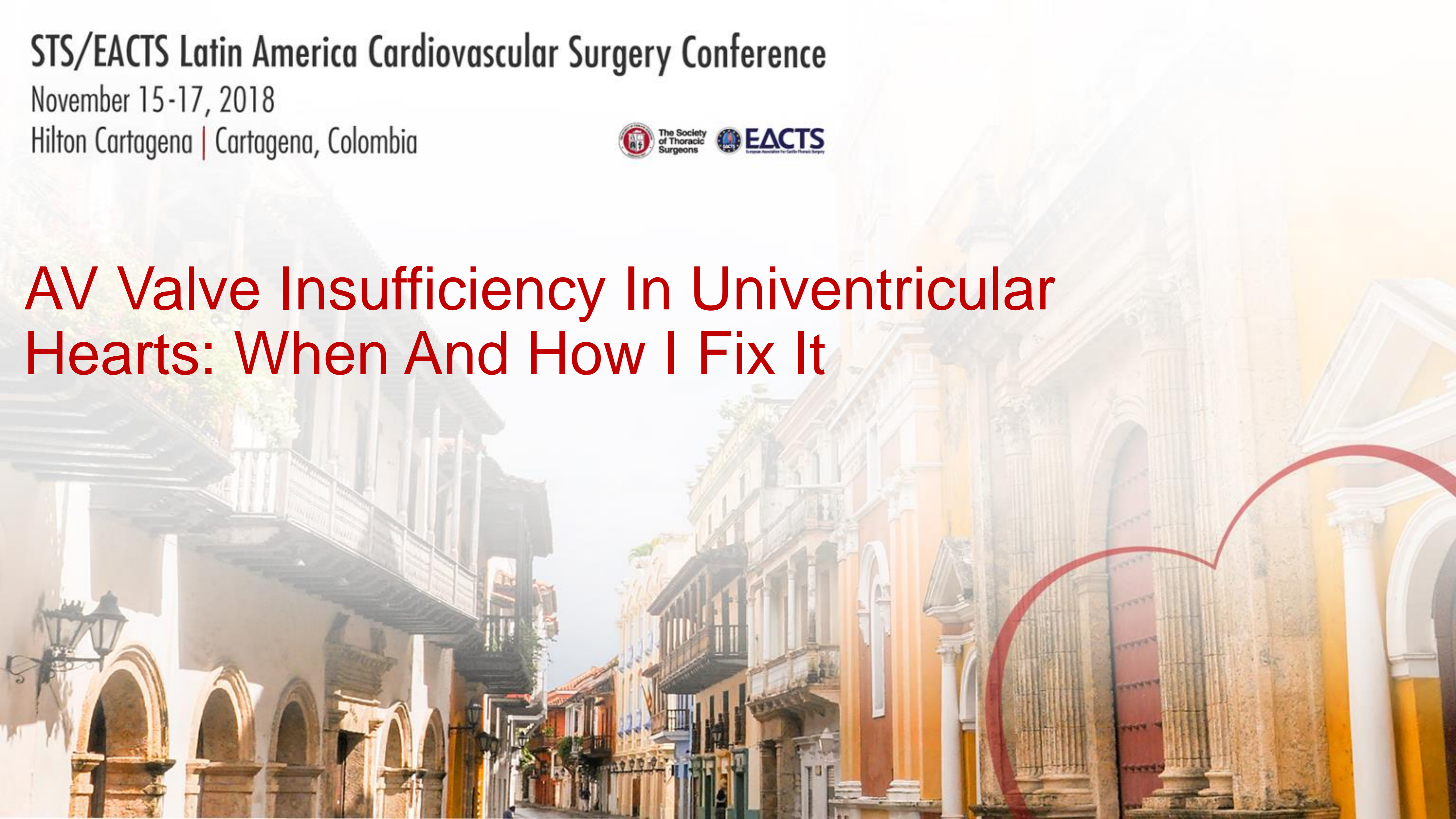

The Society
of Thoracic
Surgeons



EACTS
European Association for Cardio-Thoracic Surgery

AV Valve Insufficiency In Univentricular Hearts: When And How I Fix It



Repair of Atrioventricular Valve in Single Ventricle

Pedro J. del Nido, M.D.
Boston Children's Hospital
Harvard Medical School

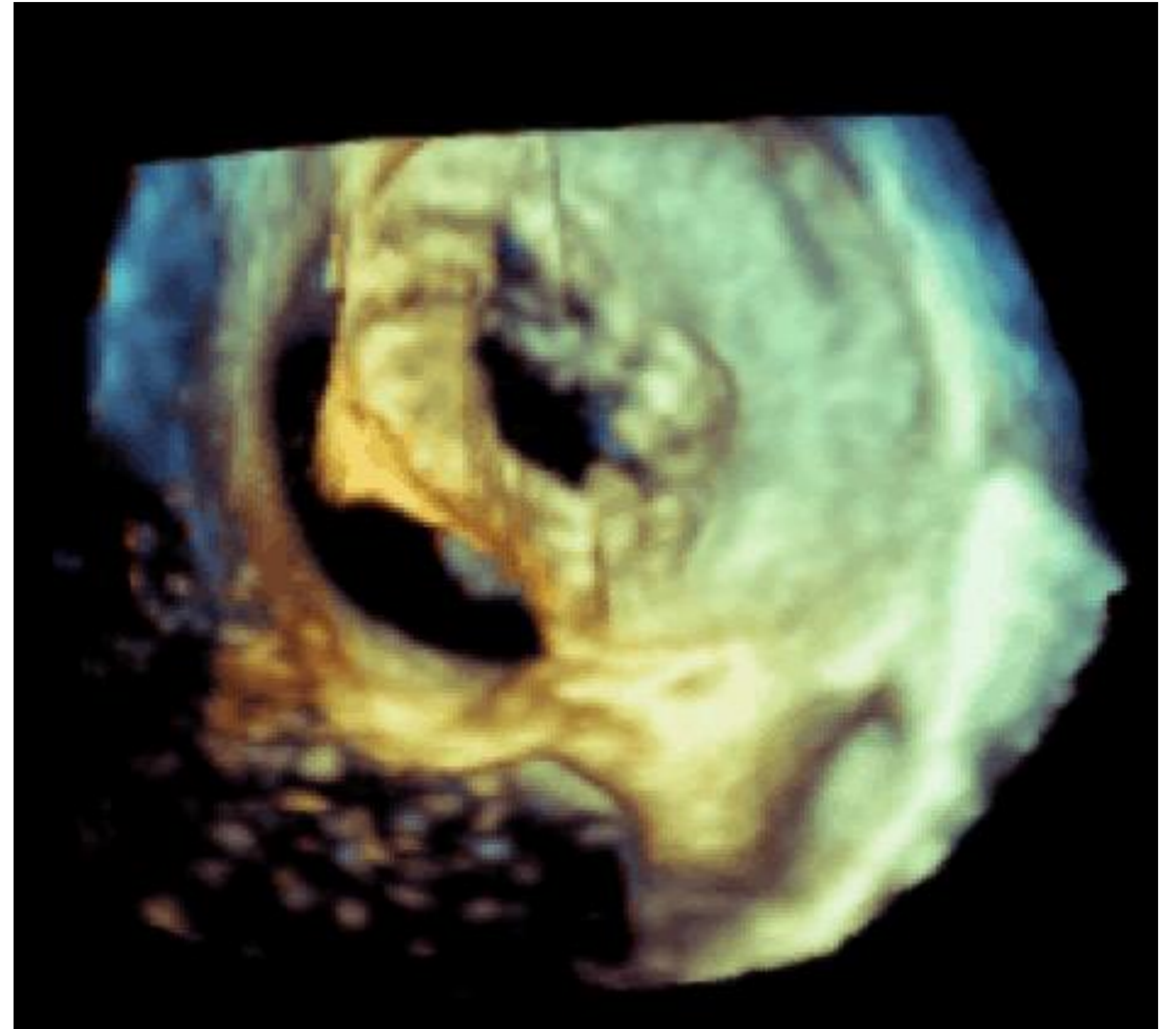


No Disclosures

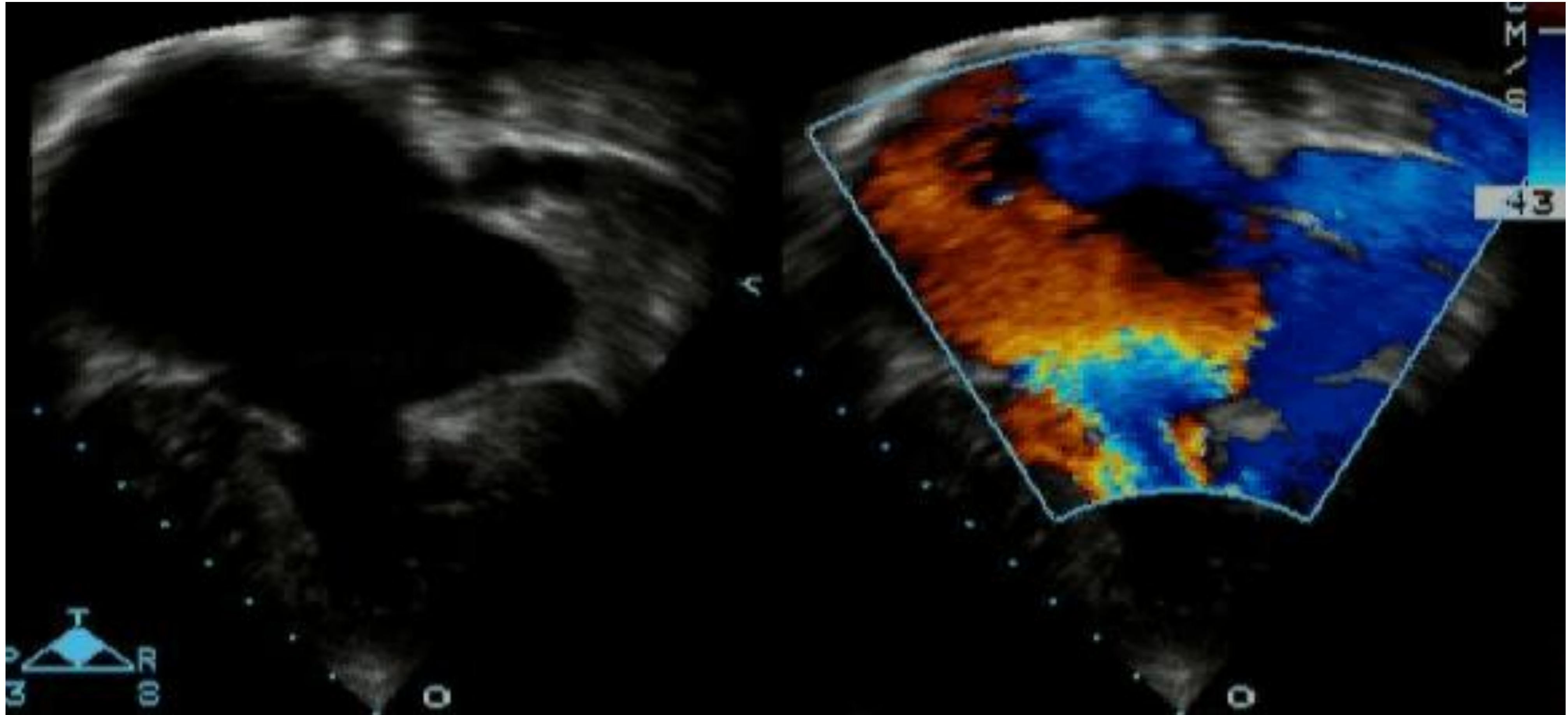


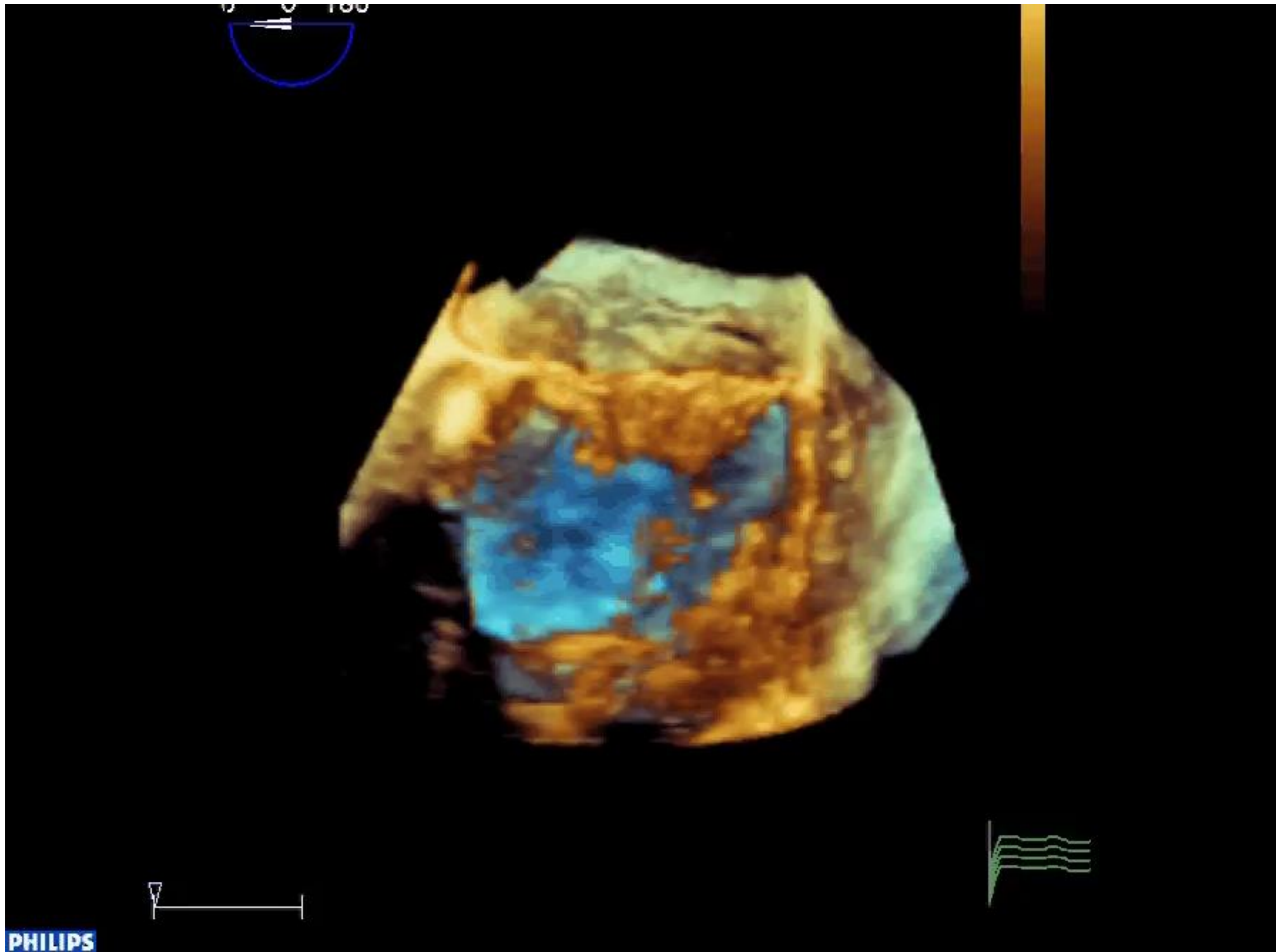
Pre-operative assessment

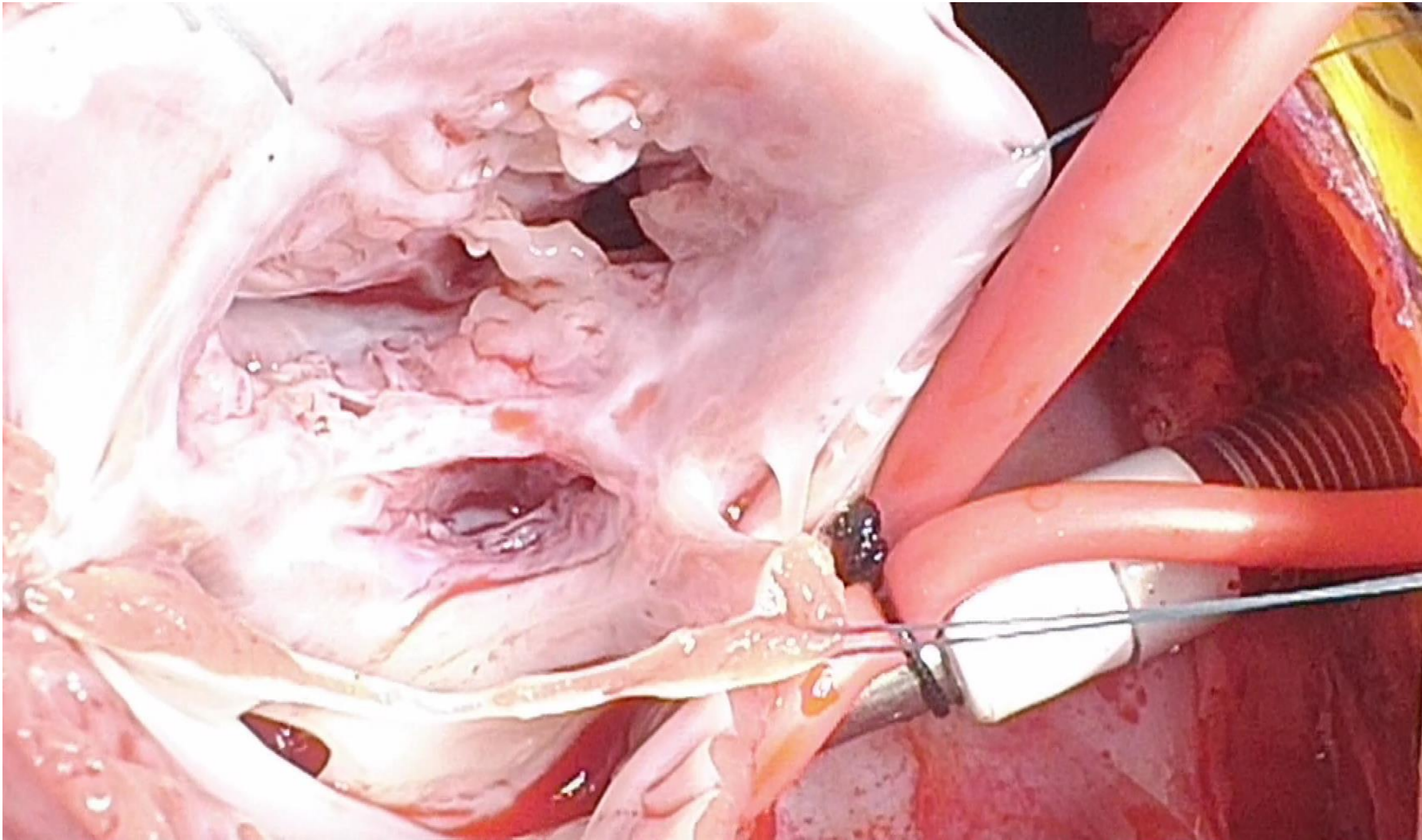
- Leaflet mobility
- Papillary muscle location (left AV valve)
- Total annulus diameter/2
 - Not a circular valve
- Position over septum (?)
- Mechanism of dysfunction
 - Hypermobility, restriction, annular dilation

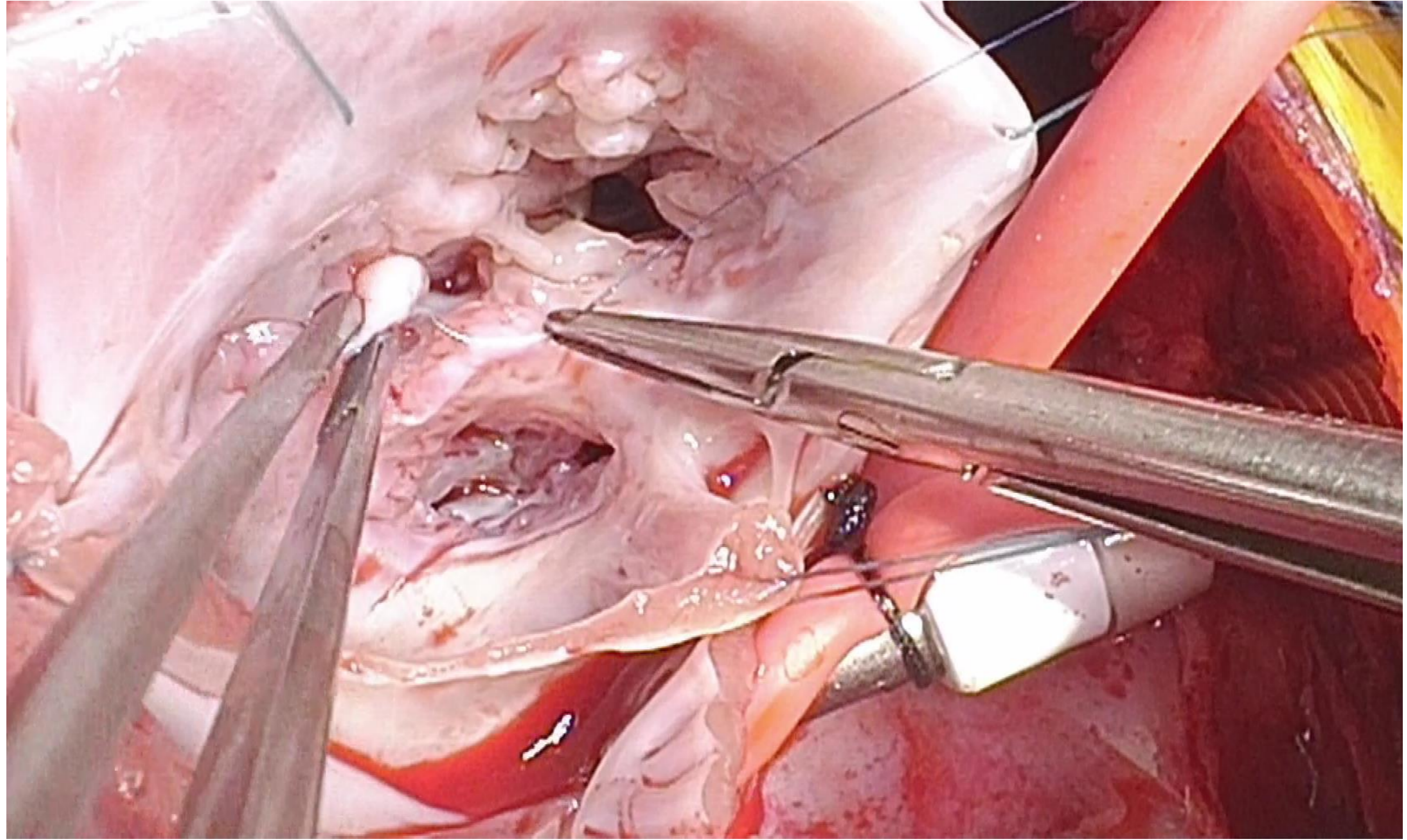
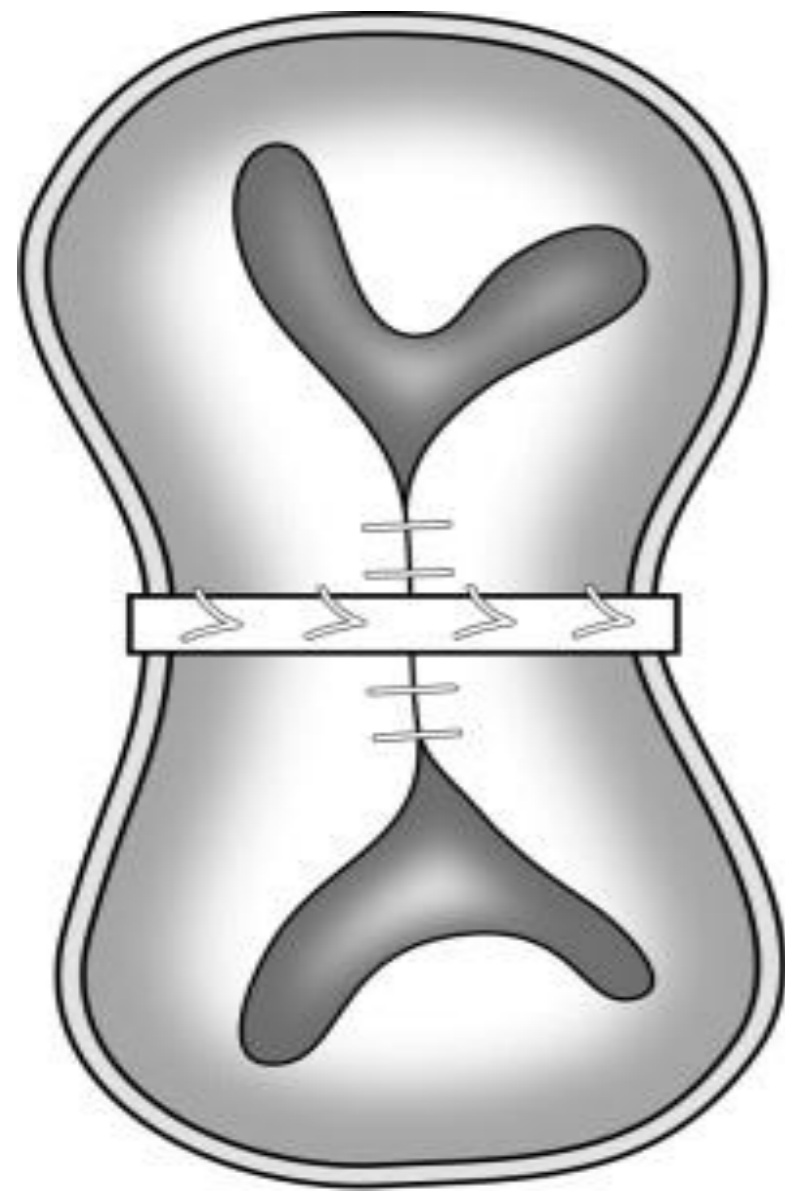


Common AV valve regurgitation:

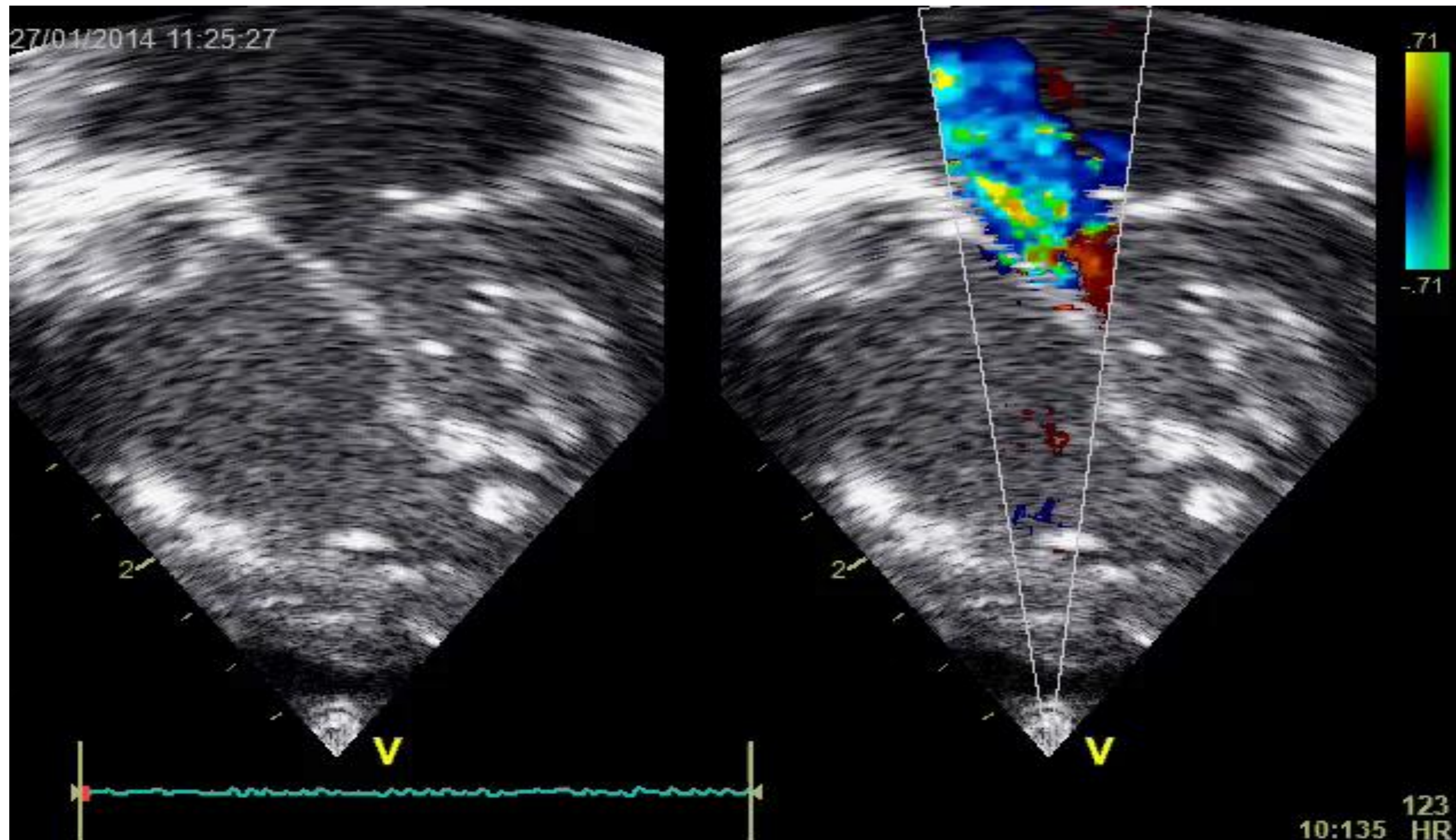




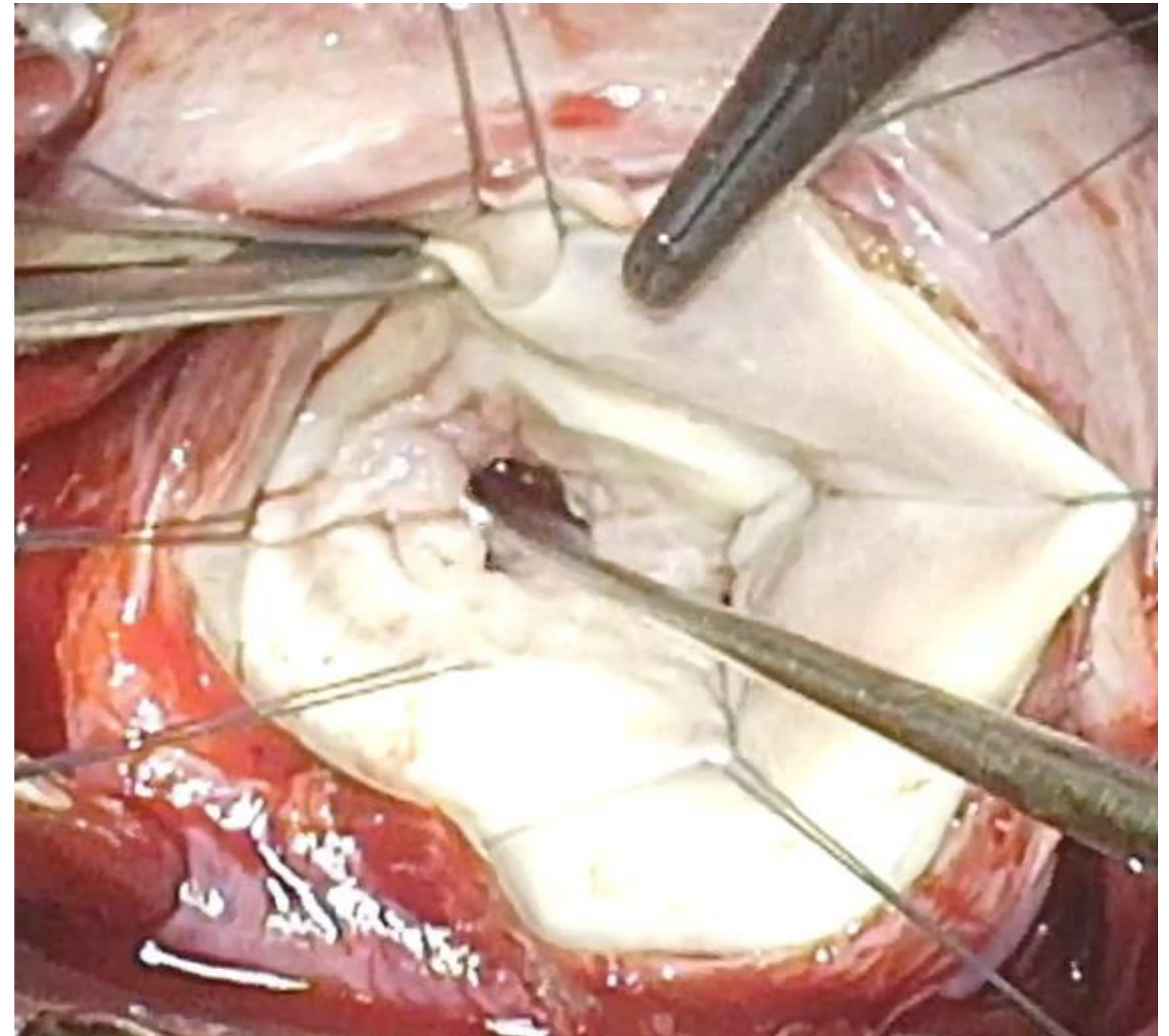
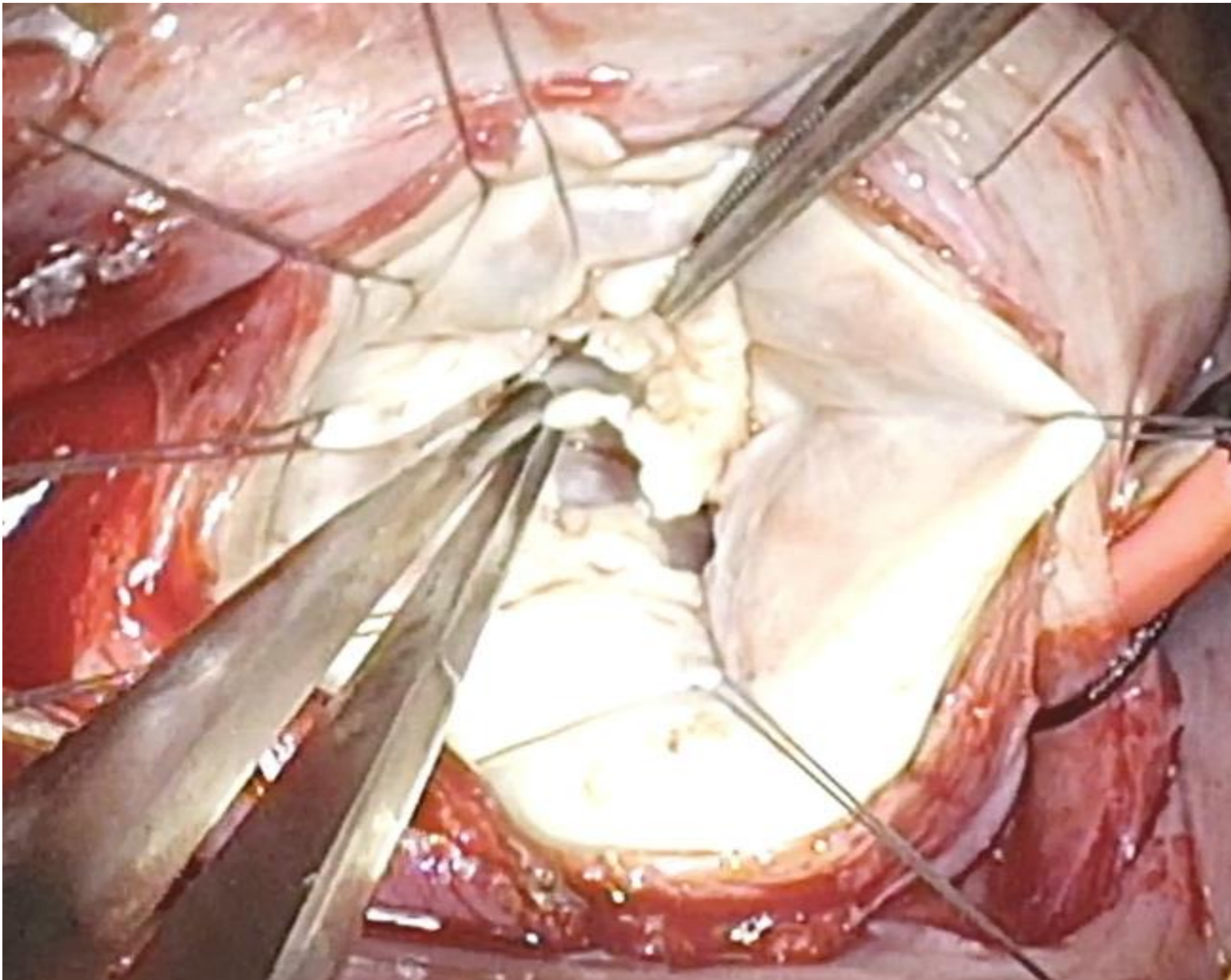




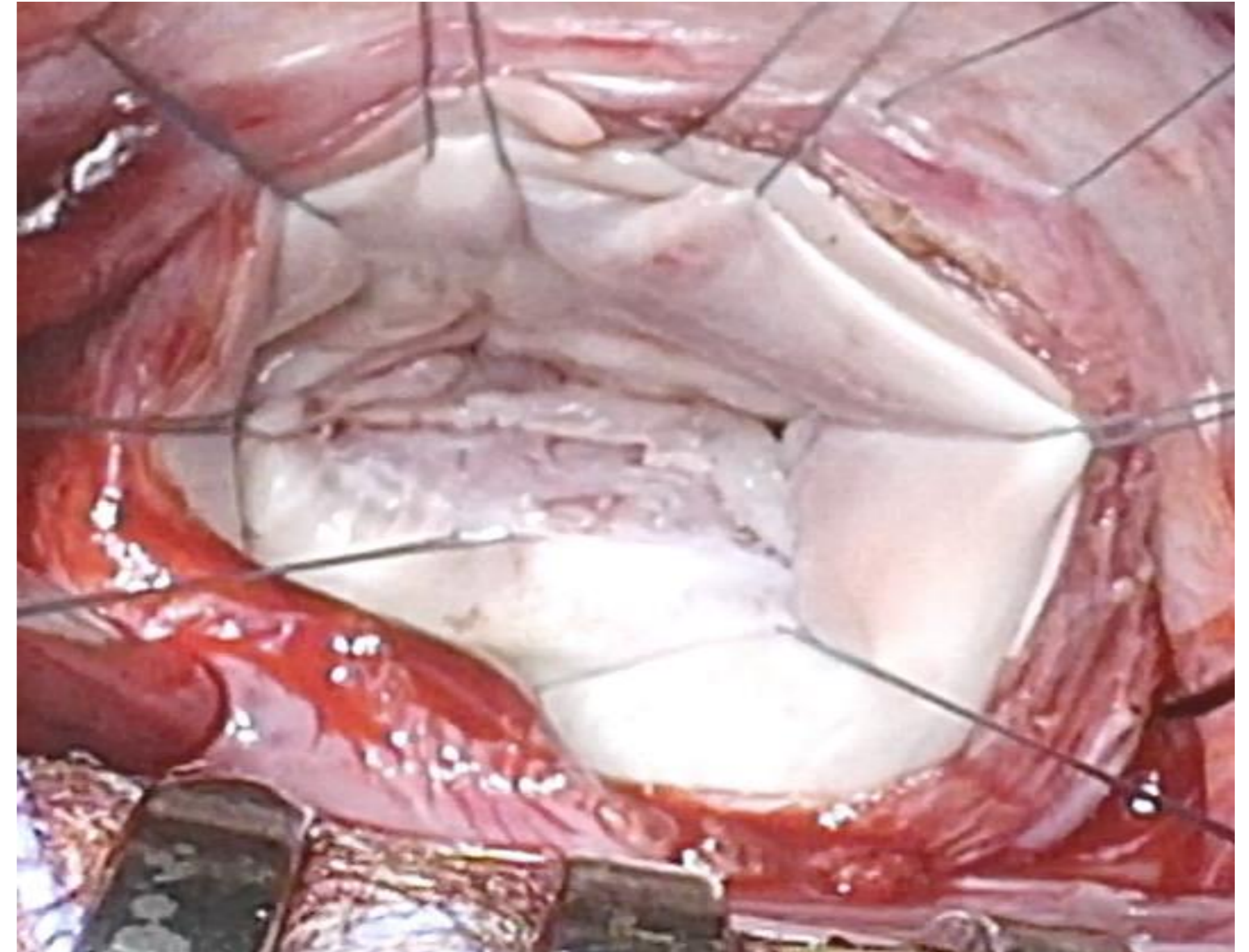
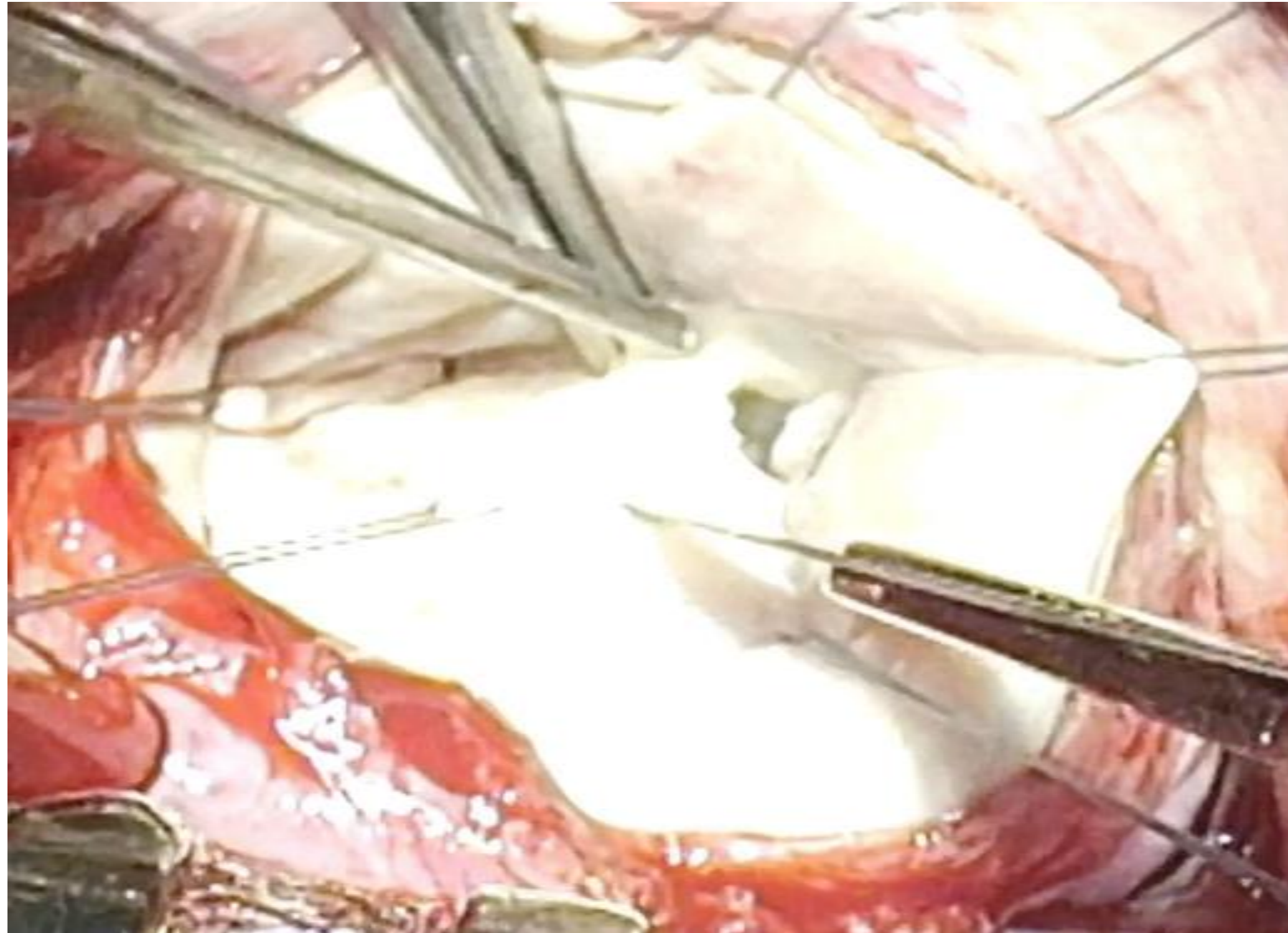
Tethered or Deficient Leaflets



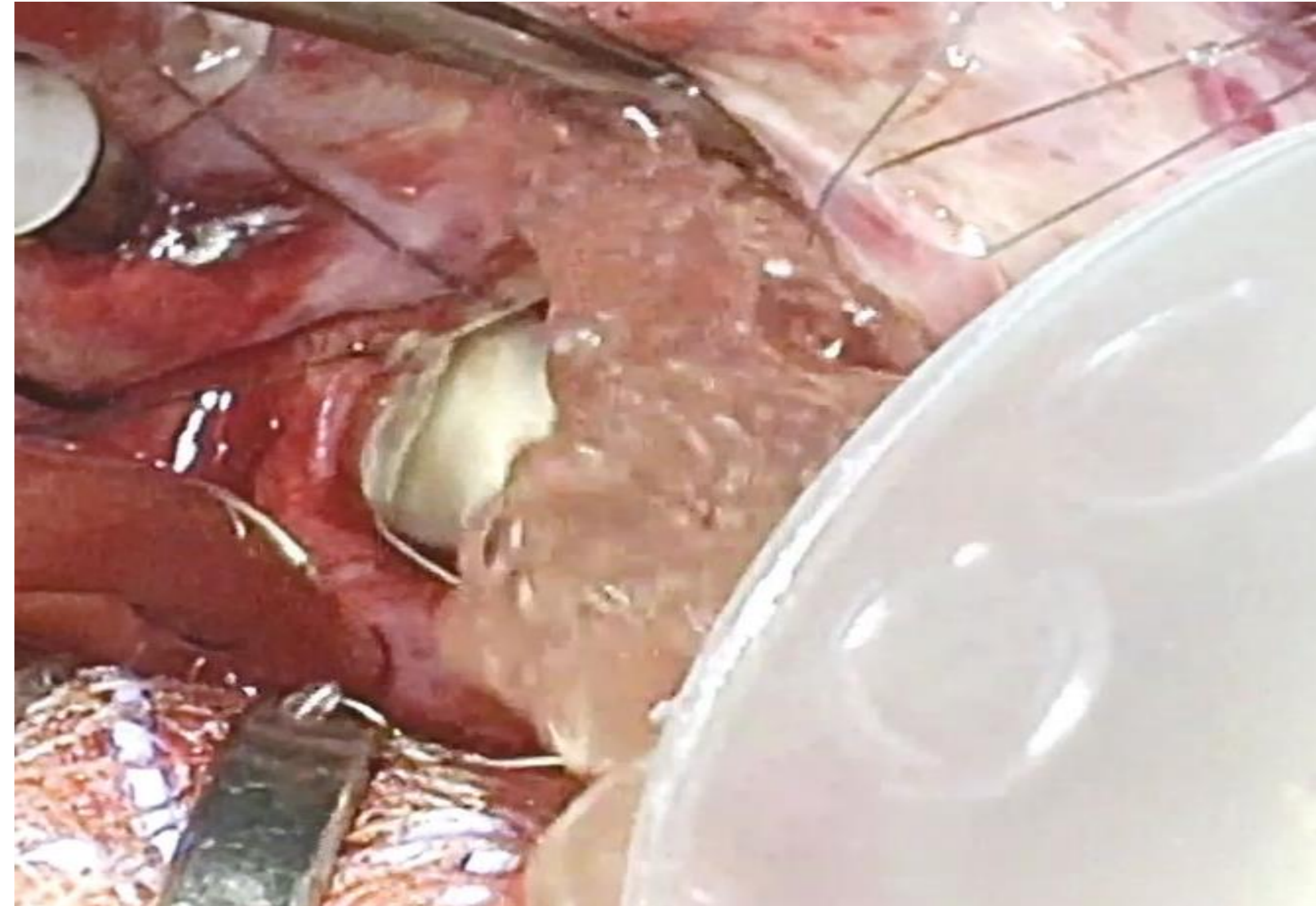
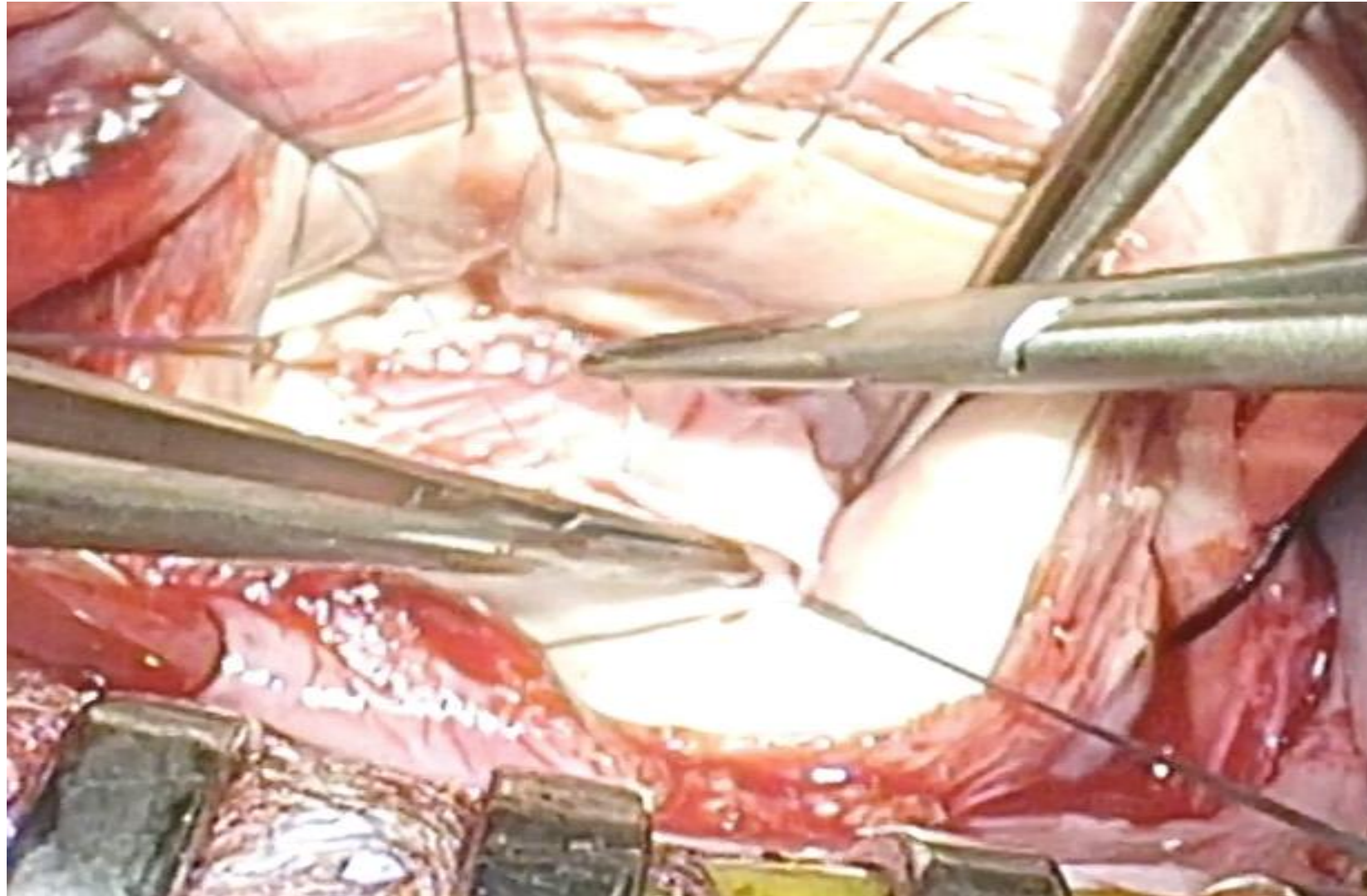
Leaflet support: Chordal transfer



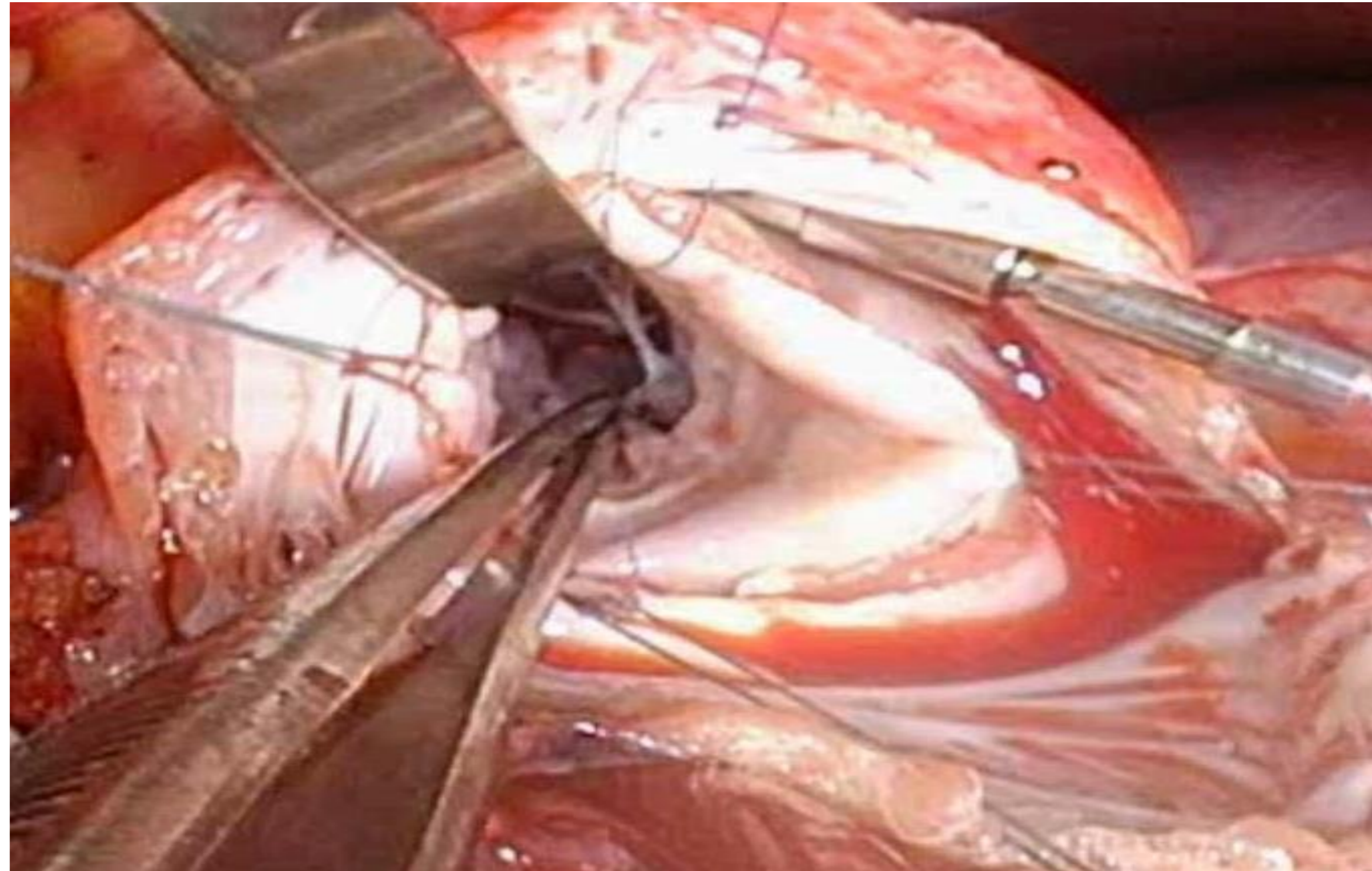
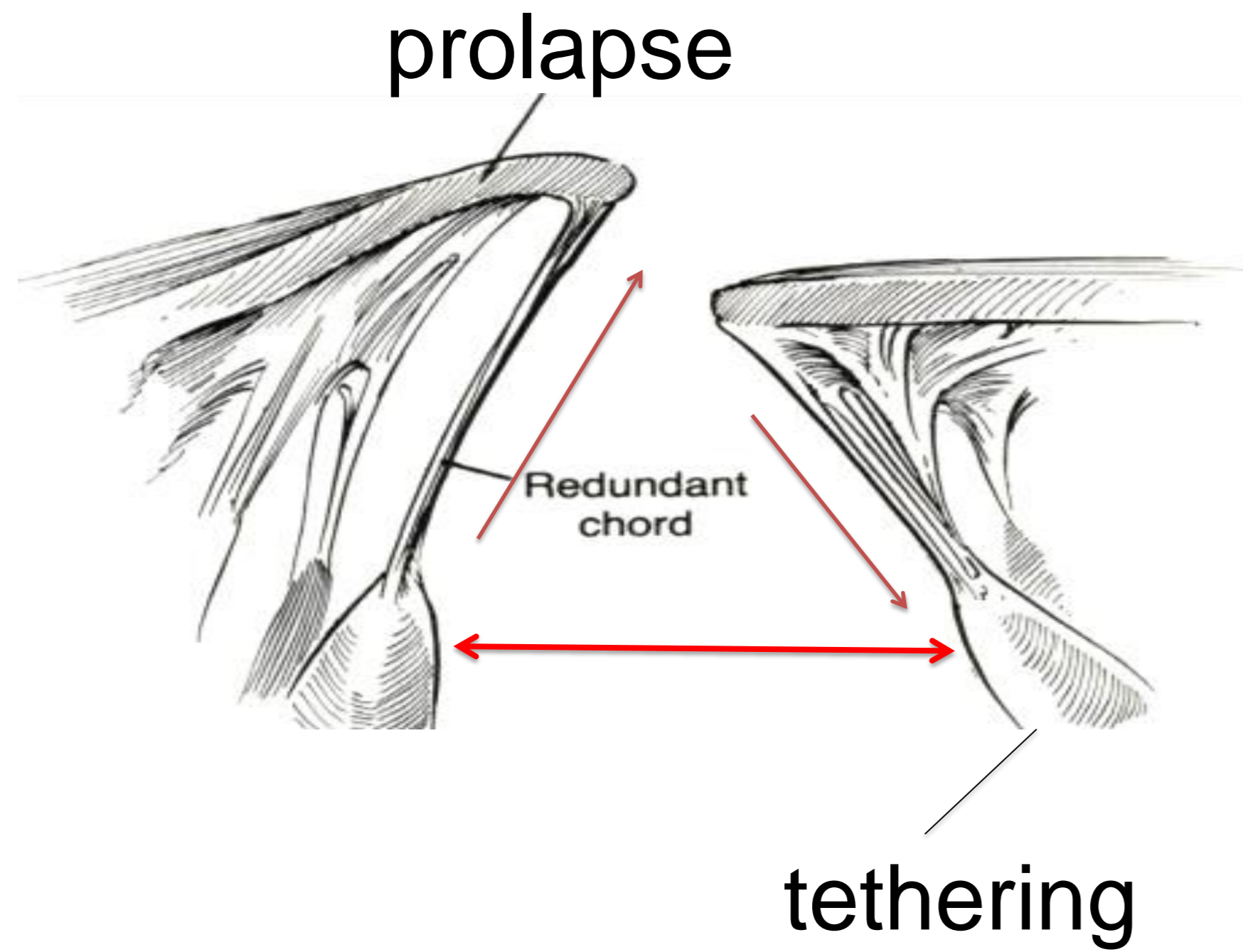
Posterior leaflet detachment and augmentation



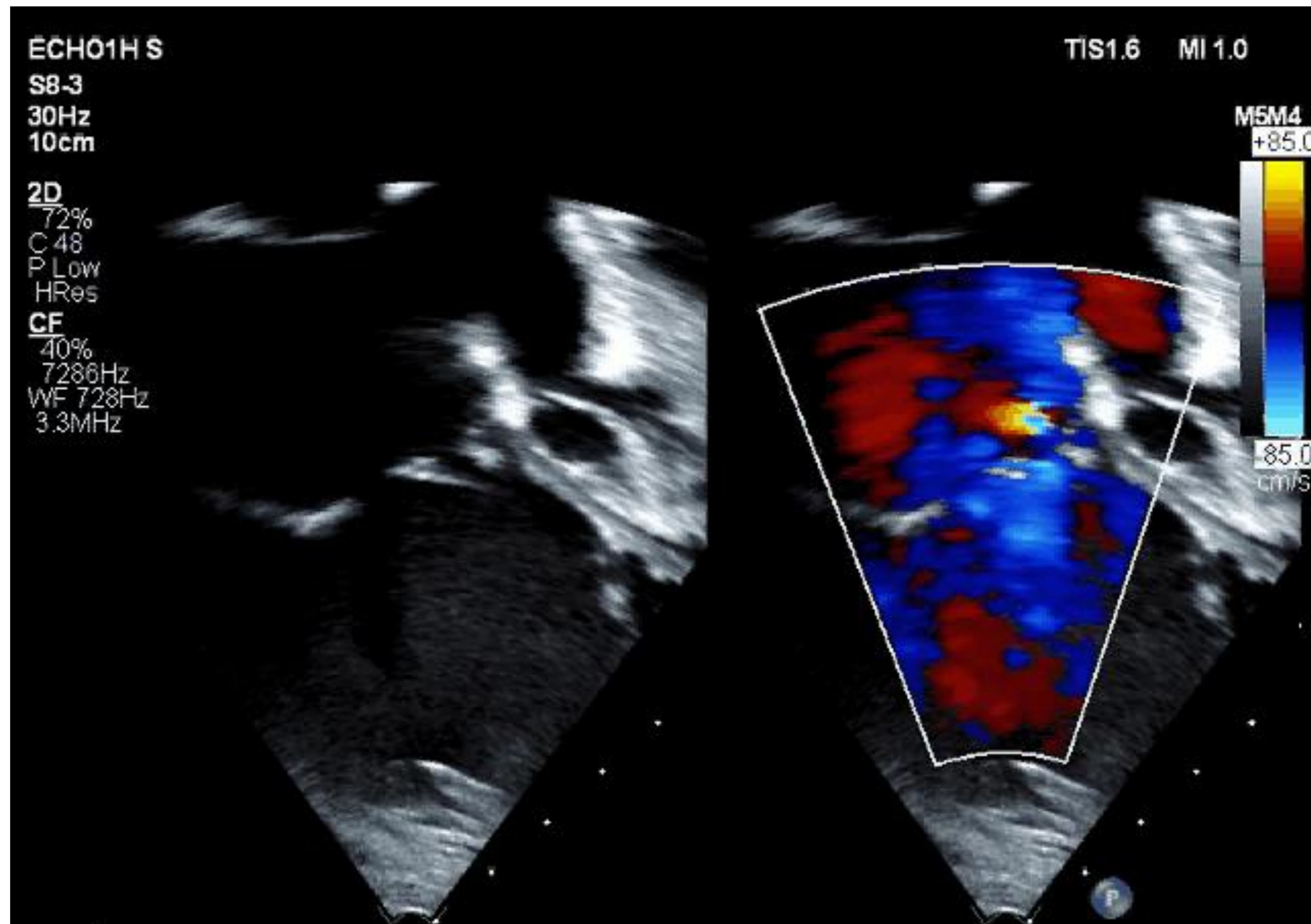
Pericardial patch augmentation

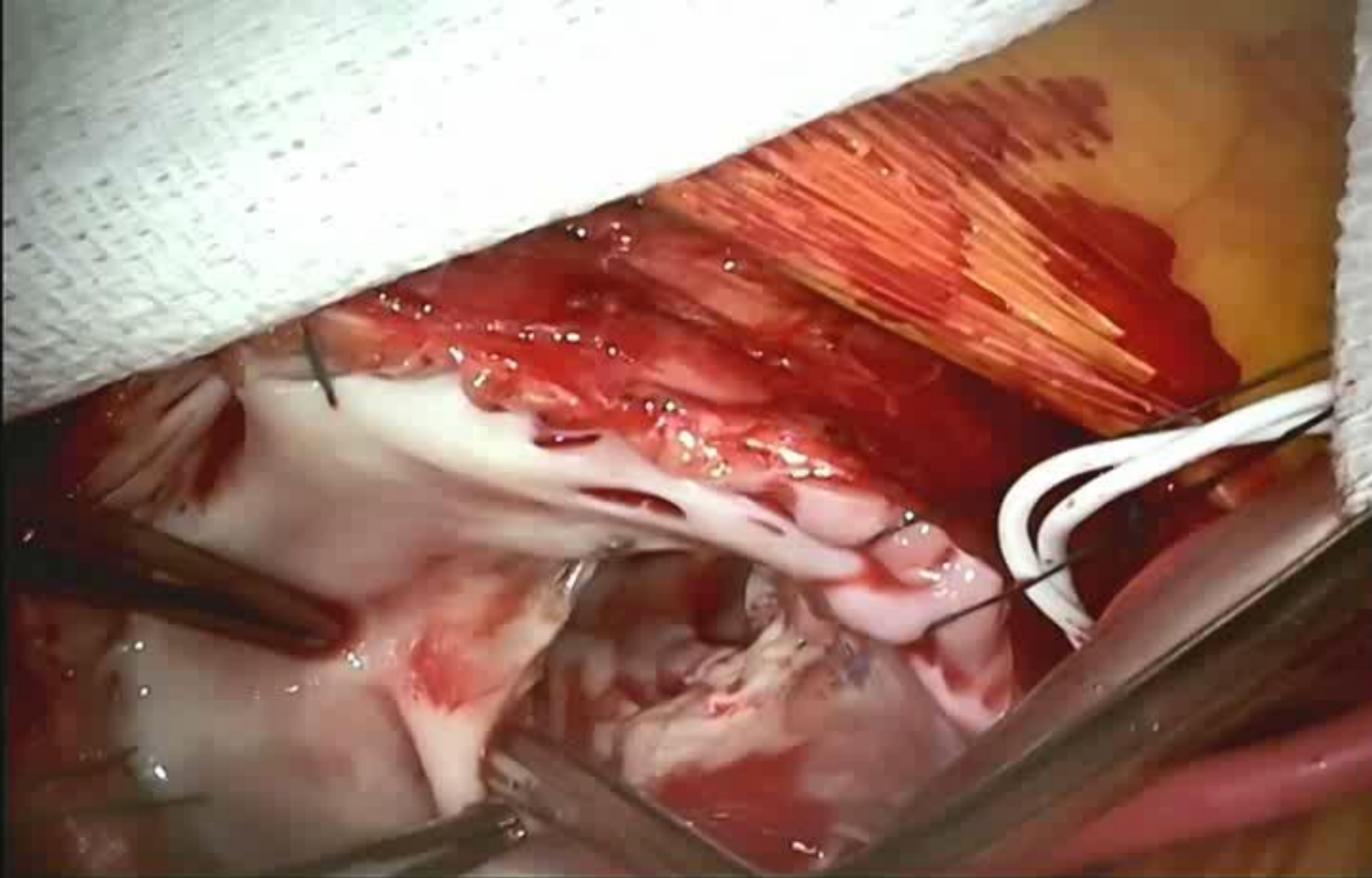


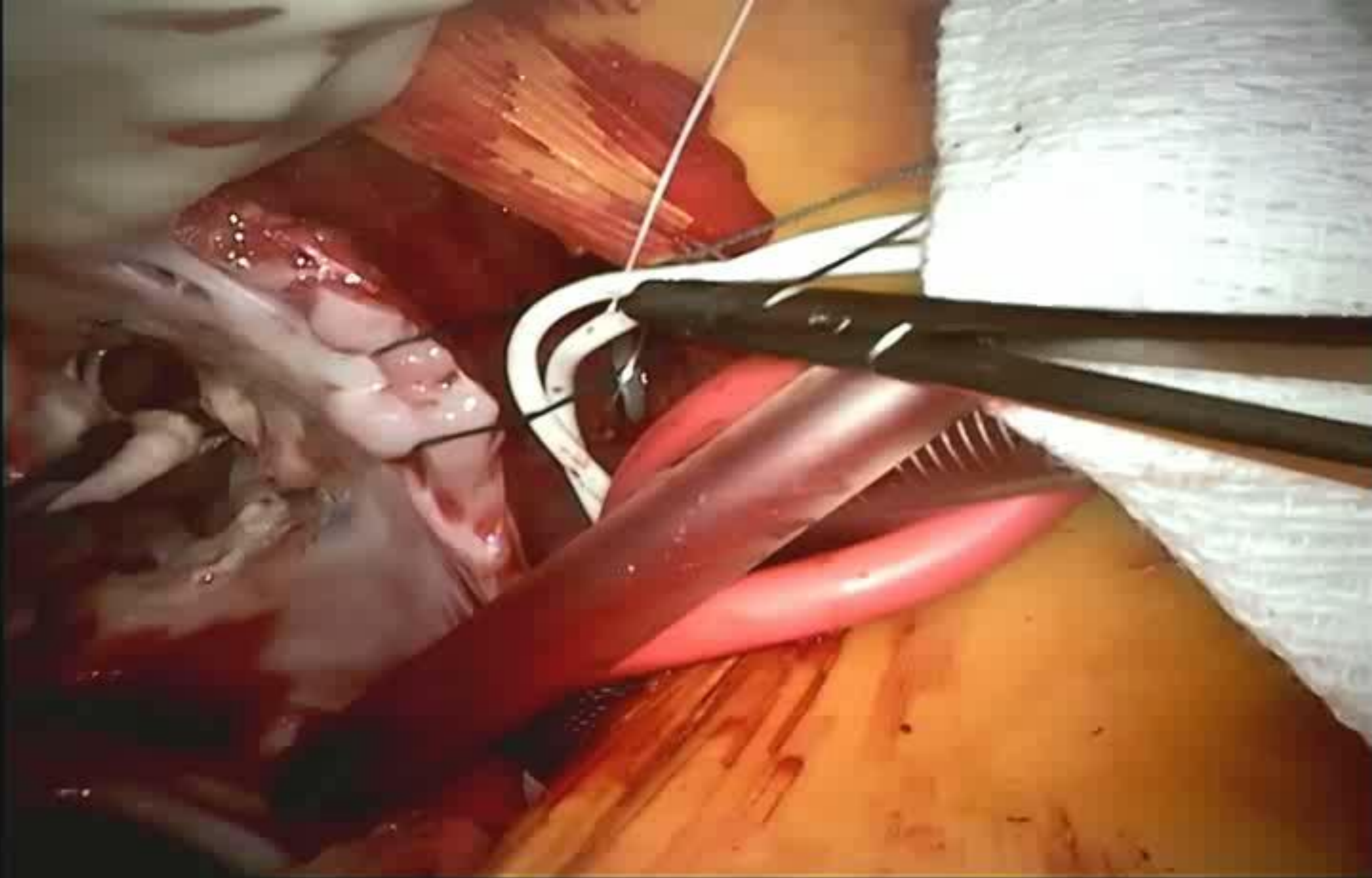
Papillary muscle approximation

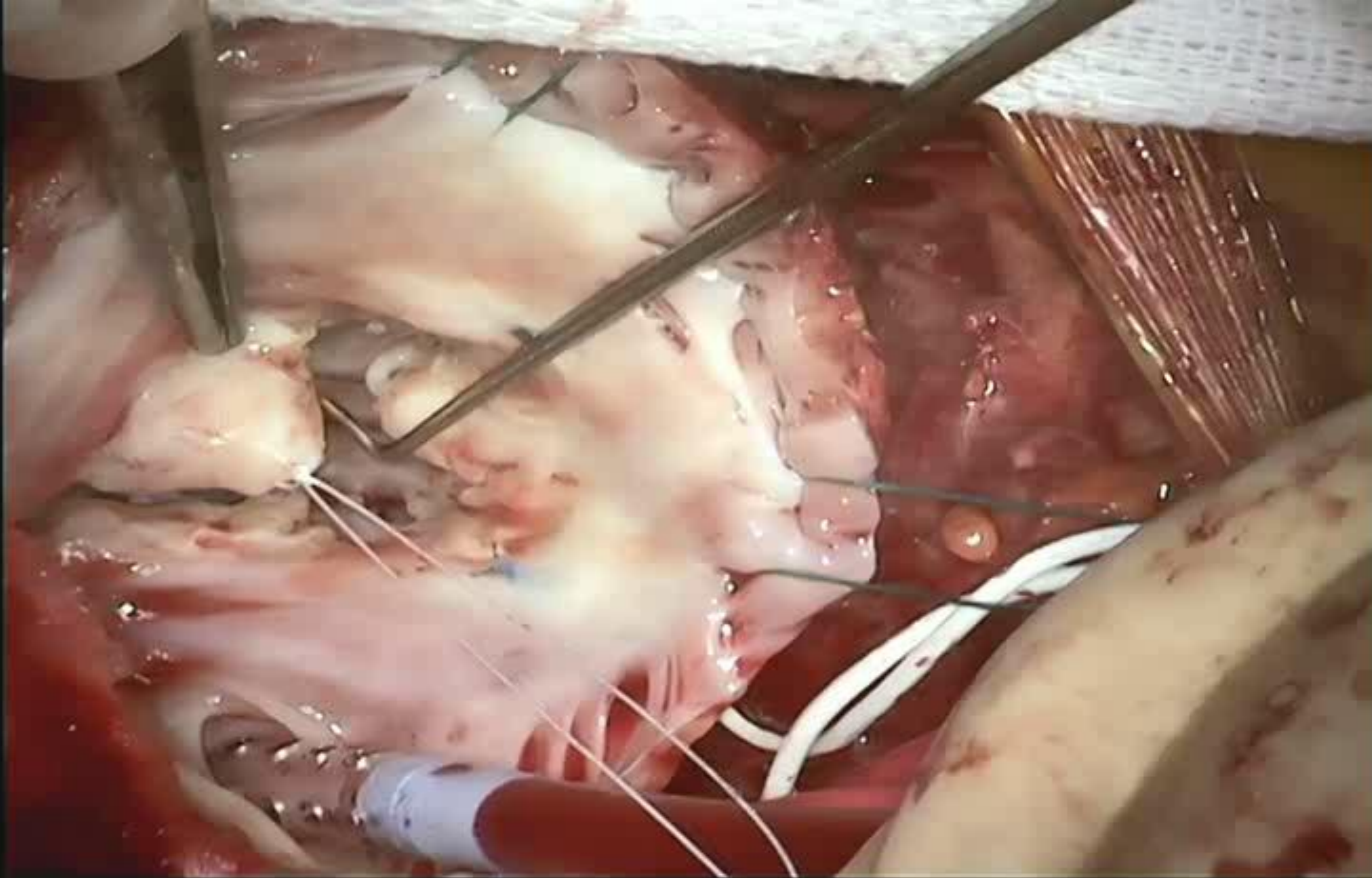


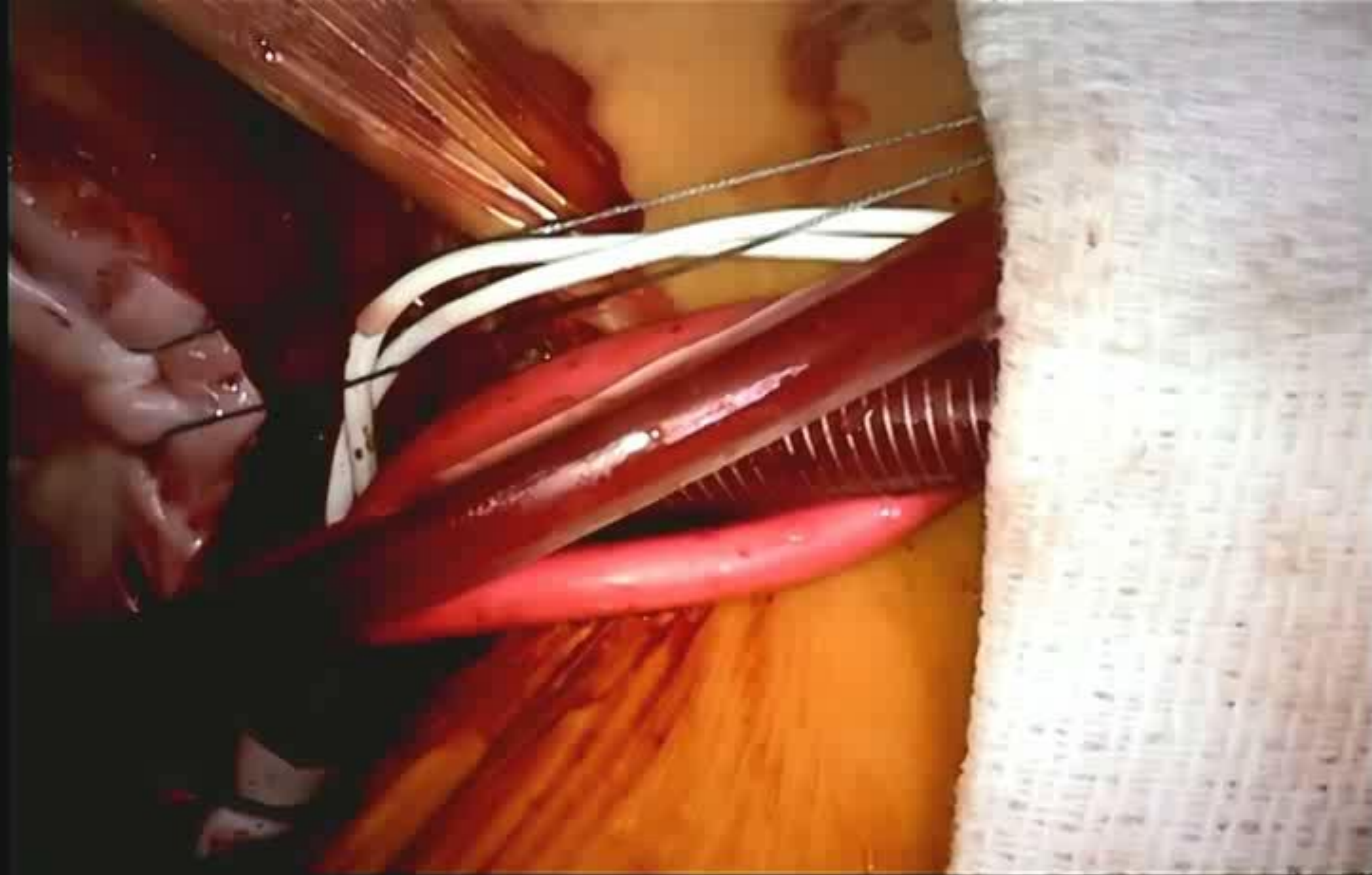
Pre-operative echo HLHS



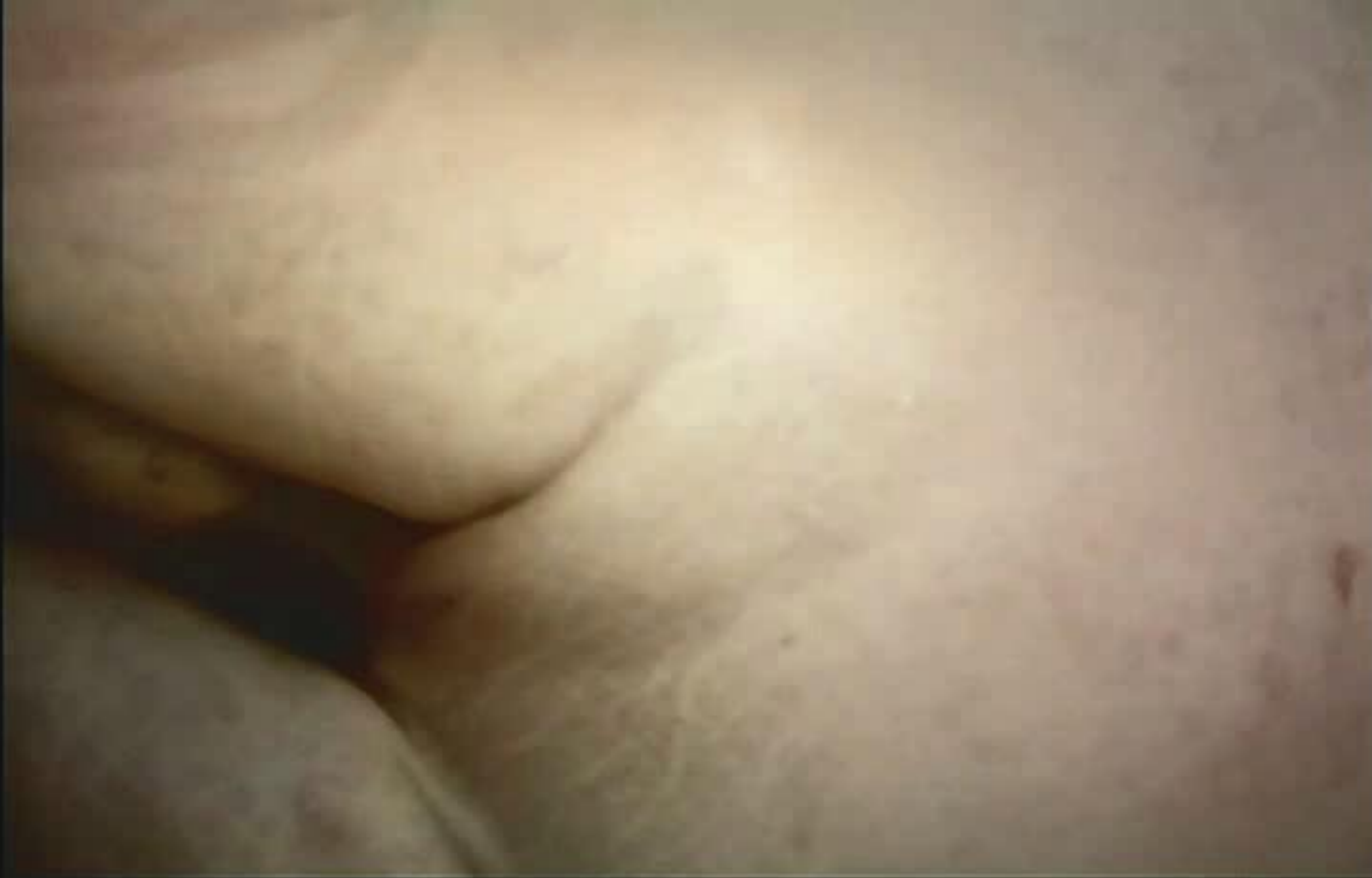












Regurgitant AV valve

- Leaflet mobility
- Papillary muscle location (left AV valve)
- Total annulus diameter/2
 - Not a circular valve
- Position over septum (?)
- Mechanism of dysfunction
 - Hypermobility, restriction, annular dilation

Thank you