



Update on Off-Pump Transapical MV Repair

Vinod H. Thourani, MD

**Professor of Surgery
Chairman, Department Cardiac Surgery
MedStar Heart and Vascular Institute
Georgetown University School of Medicine**

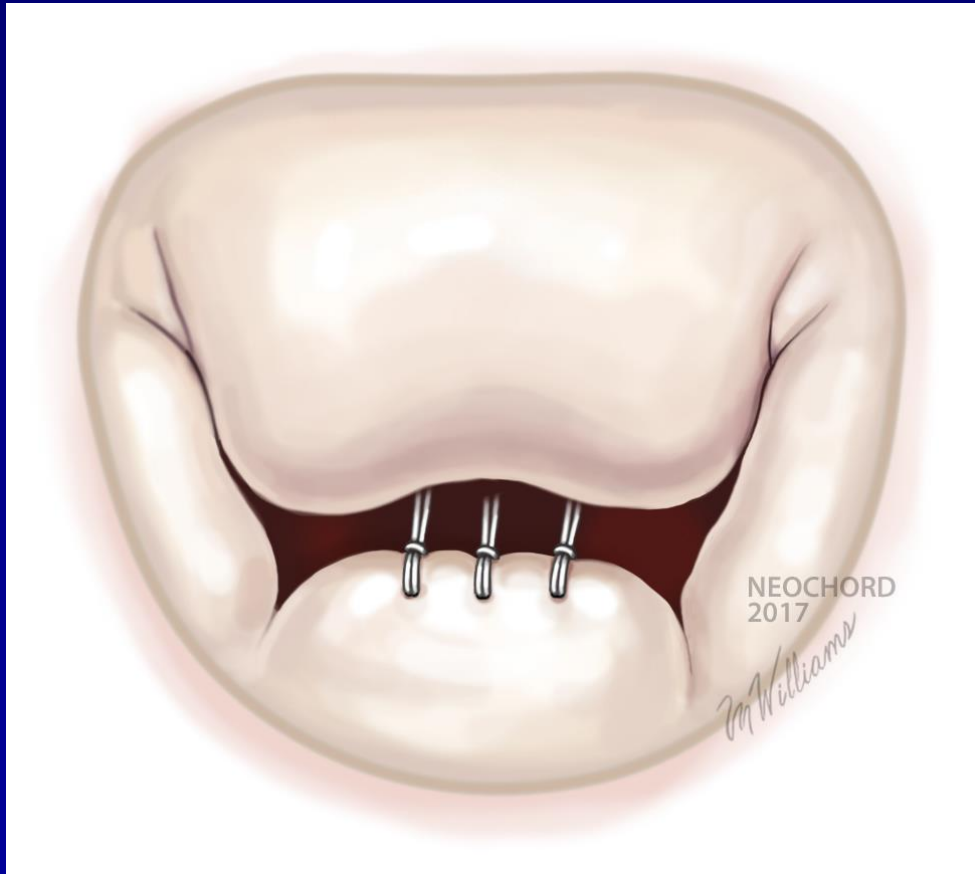
**STS/EACTS Latin American Meeting
November, 2018**

Disclosures

- **Abbott Vascular: Advisory Board / Research**
 - National Co-PI: Tendyne in Mitral MAC Trial
 - Executive Committee: SUMMIT trial
- **Boston Scientific: Consultant / Research**
 - National Co-PI: REPRISE IV trials
- **Claret Medical: Consultant**
- **Cryolife: Consultant / Research**
- **Edwards Lifesciences: Advisory Board / Research**
 - National Co-PI: ACTIVE Trial (Cardioband)
- **Gore Vascular: Consultant**
- **Jenavalve: Consultant / Research**
 - National Co-PI: TAVR trial

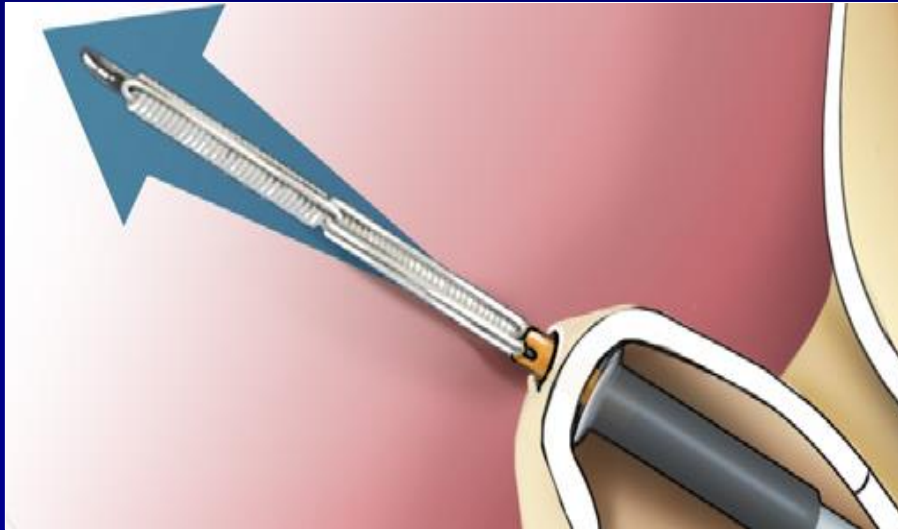
TA Chordal Repair

Preserves Future Treatment Options

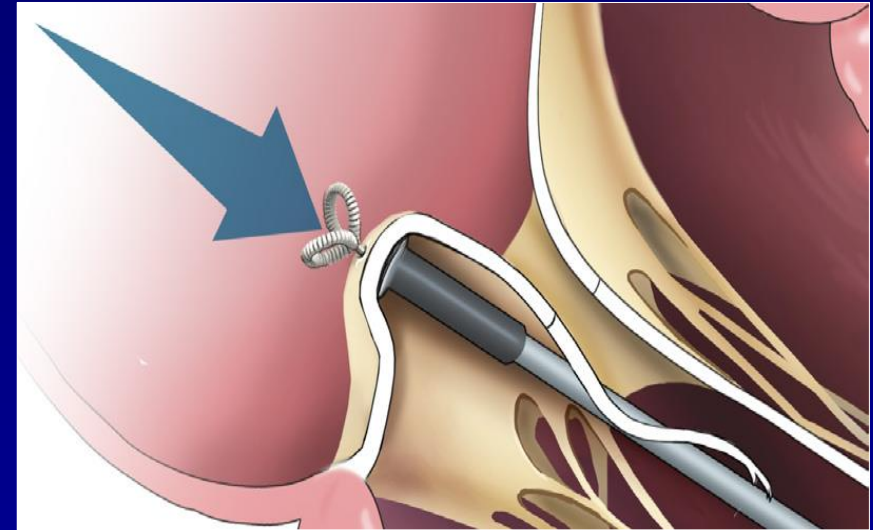


- **Mimics surgical mitral valve repair**
- **Potential for future interventional annular treatment**
- **Potential for future interventional leaflet repair or replacement**

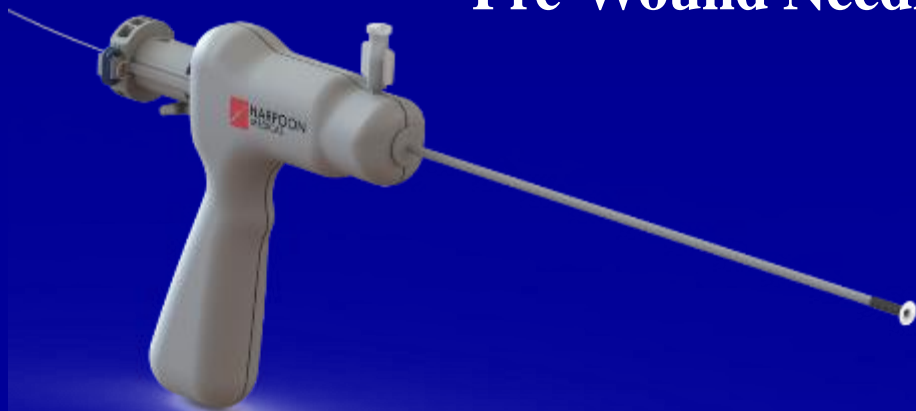Harpoon Edwards Automated Anchoring Technology



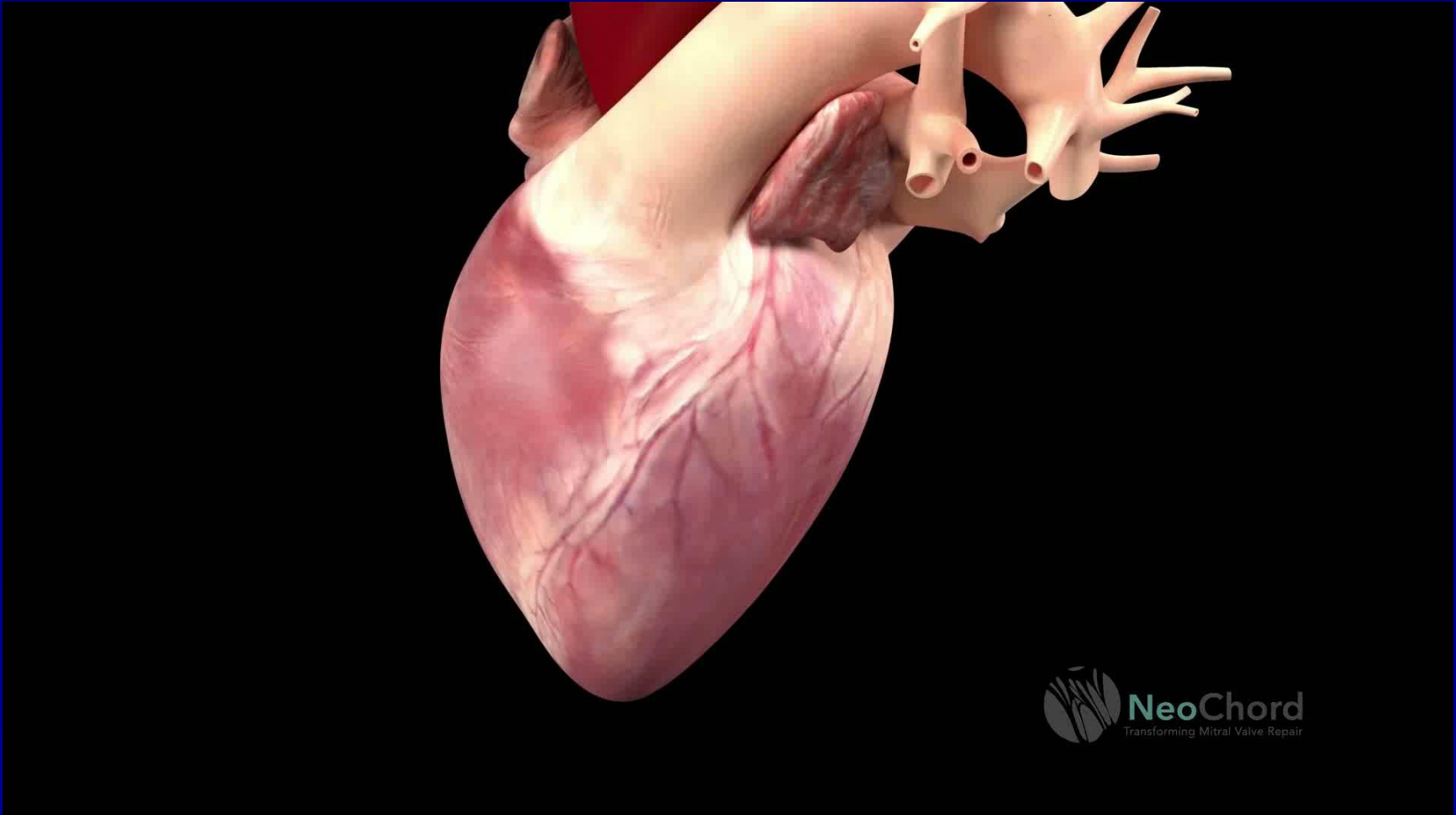
Pre-Wound Needle



Self Forming ePTFE Anchor

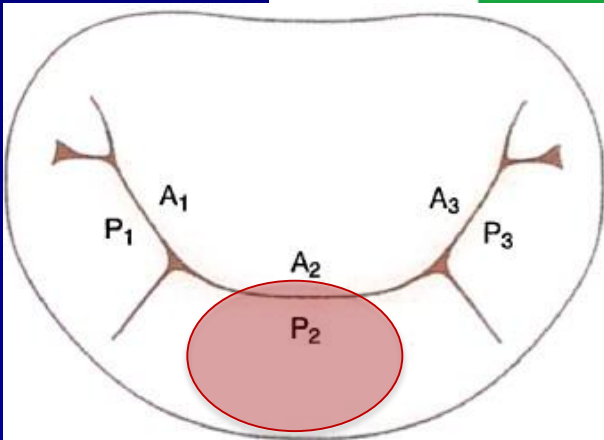
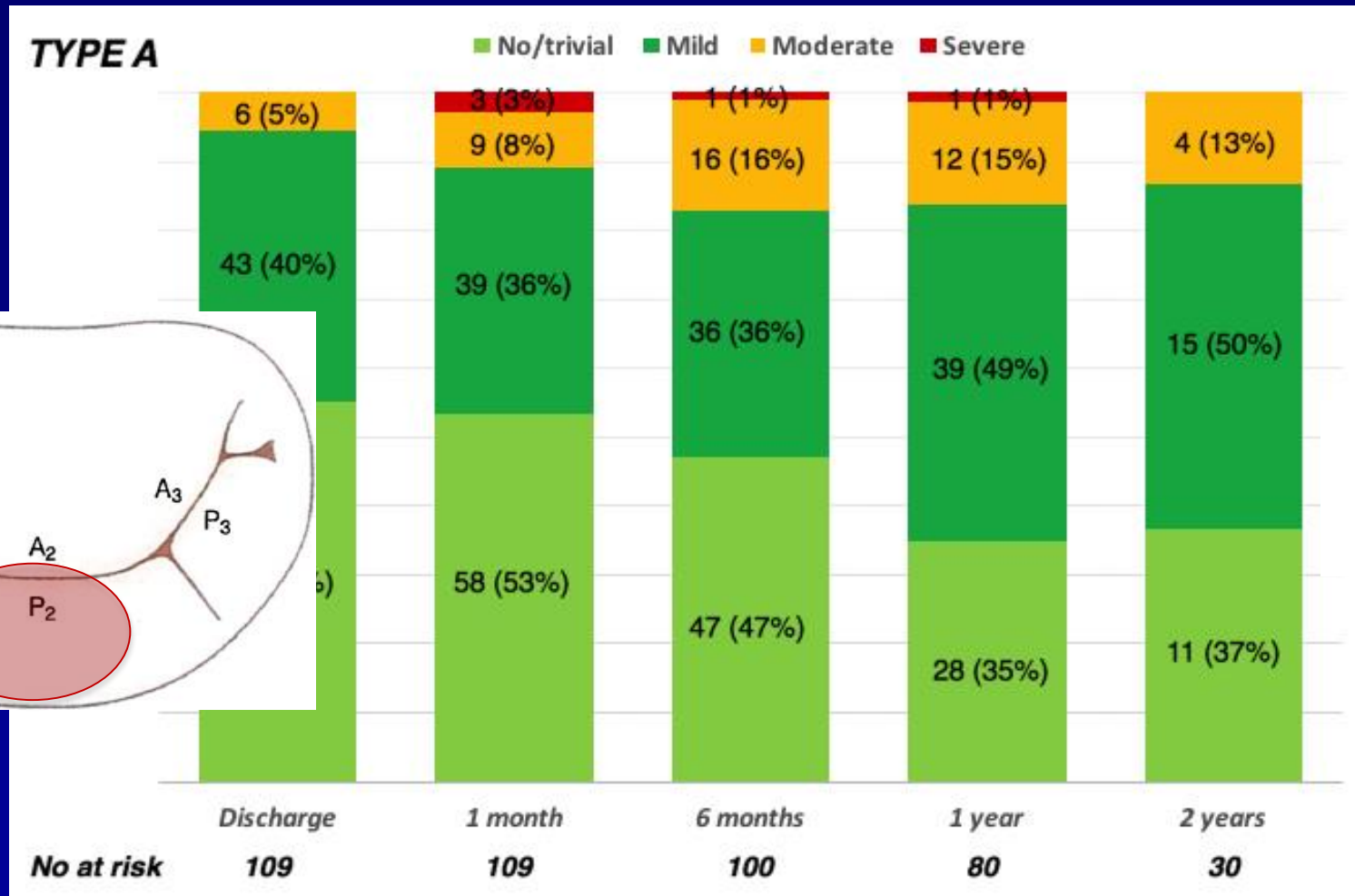


NeoChord



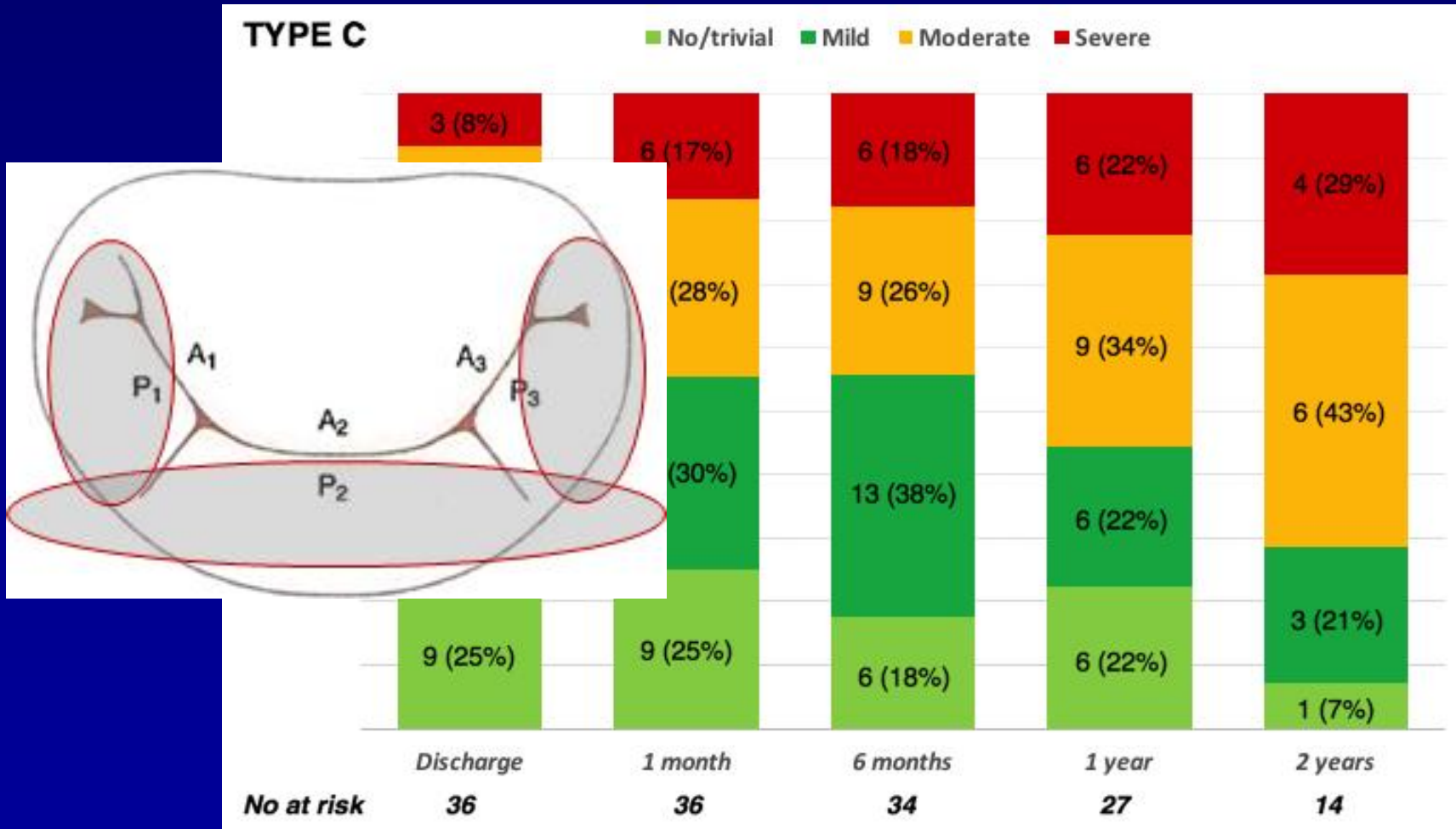
CAUTION: Investigational Device Limited by Federal (United States) Law to Investigational Use

NeoChord MR for Type A



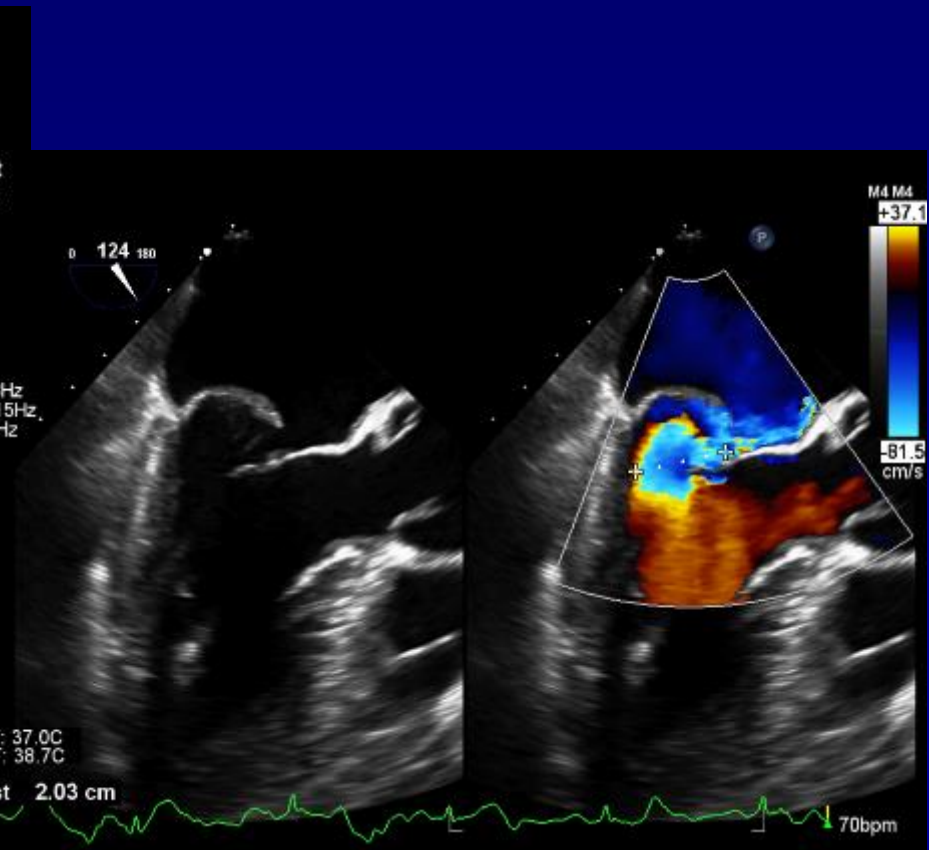
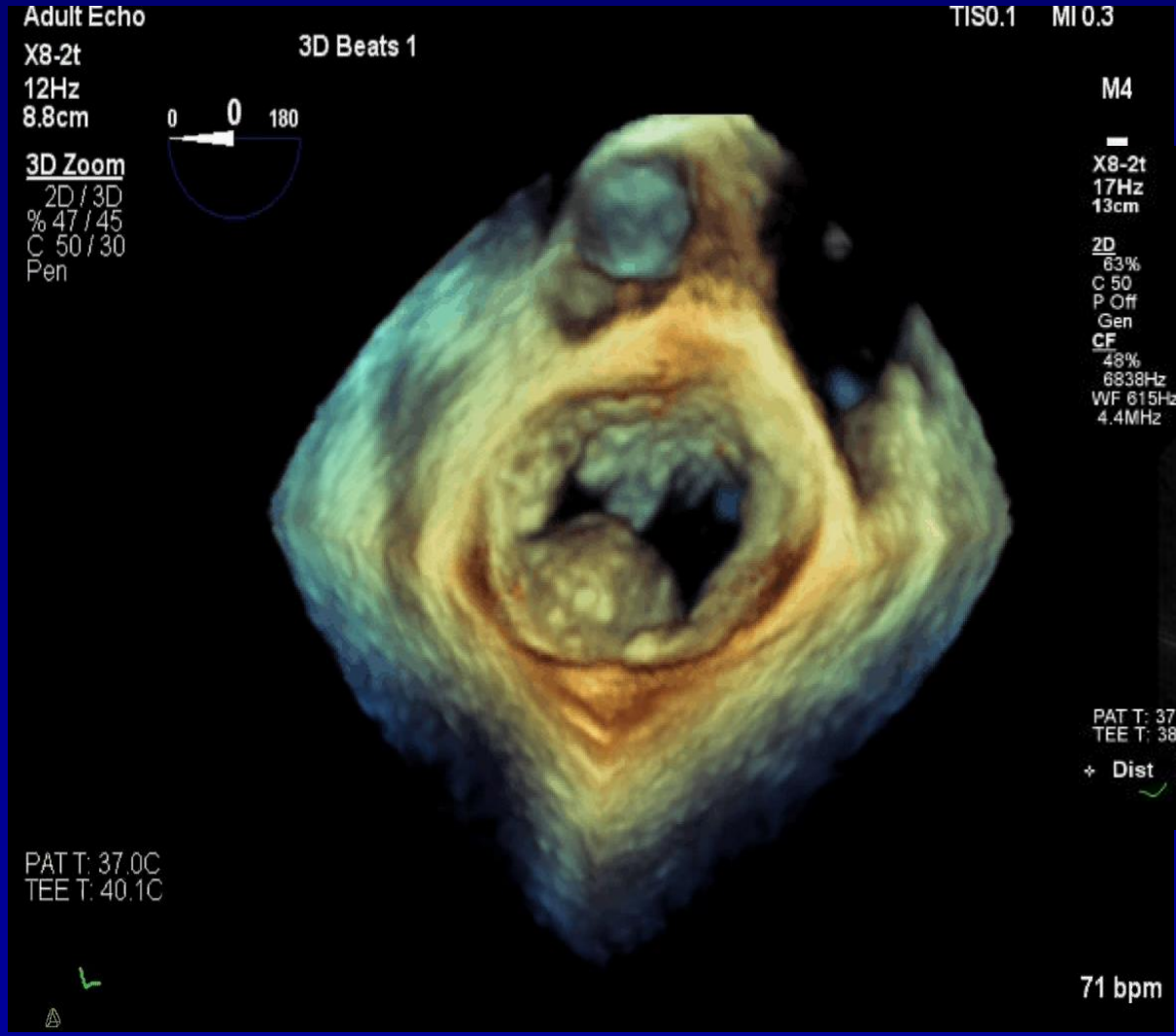
**87% ≤
MILD**

NeoChord MR for Type C

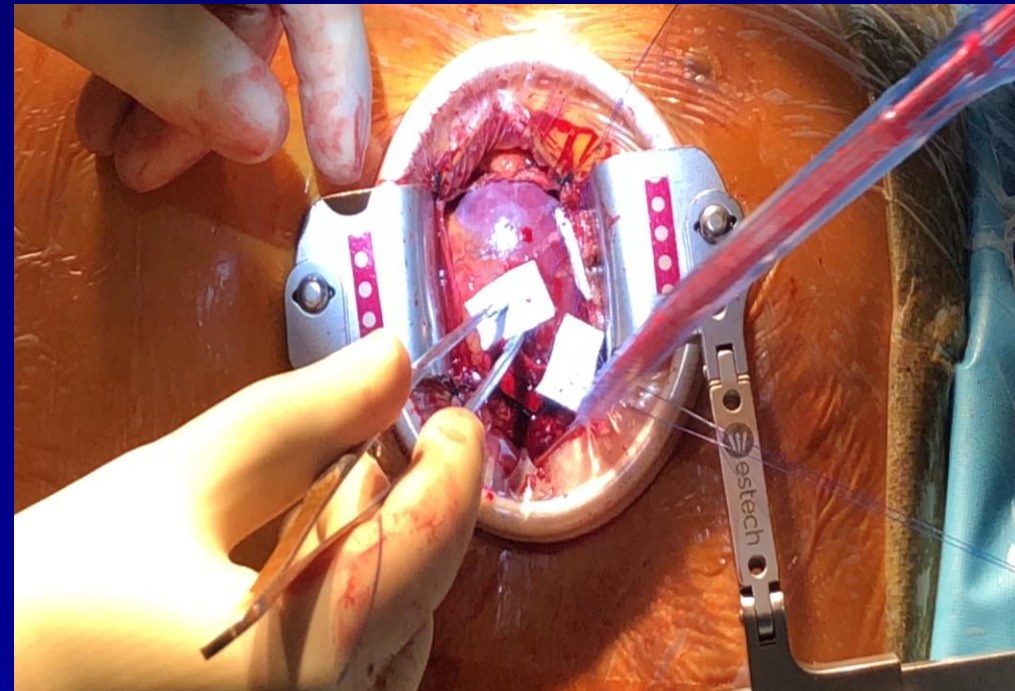
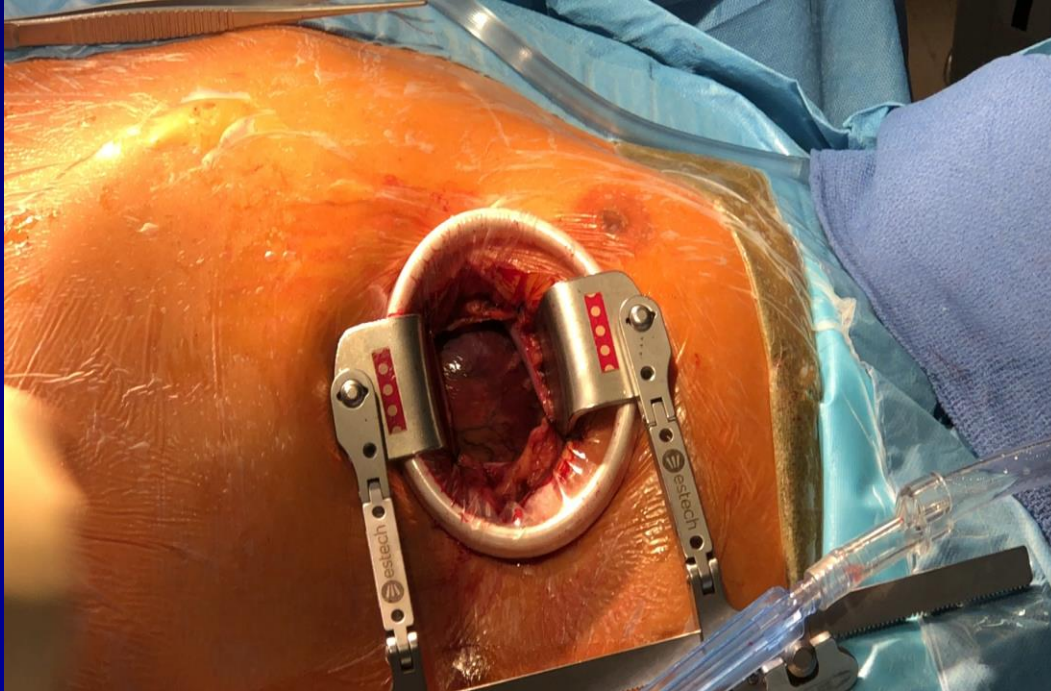


**28% ≤
MILD**

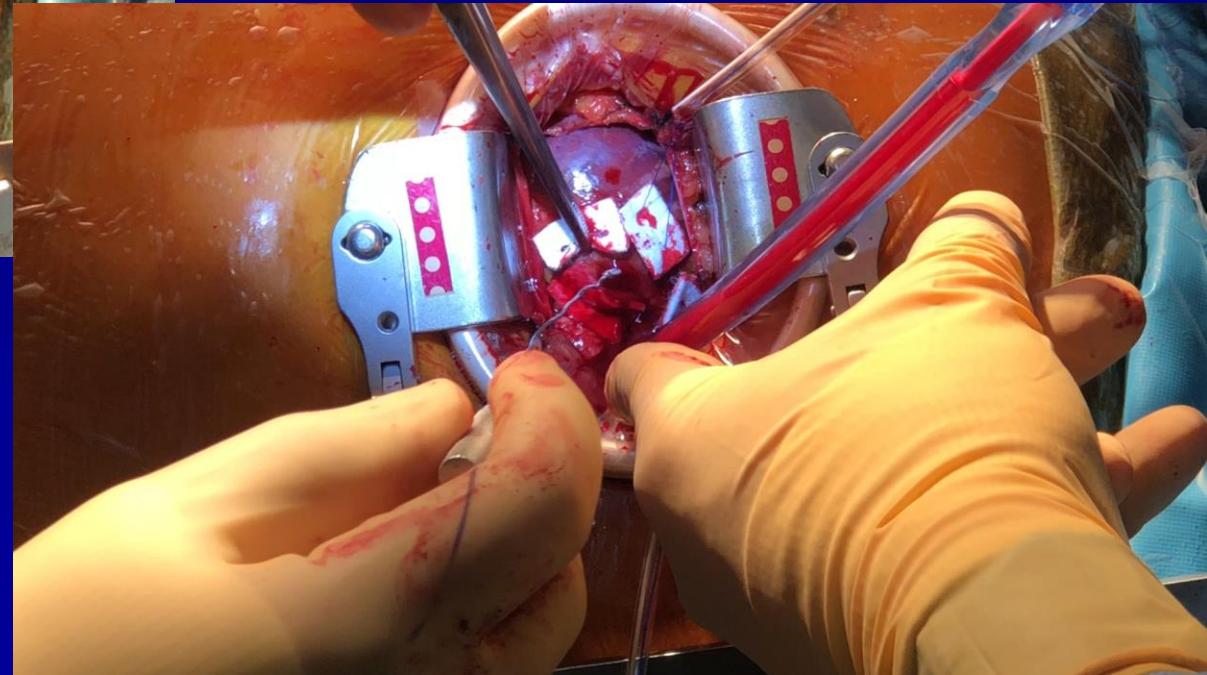
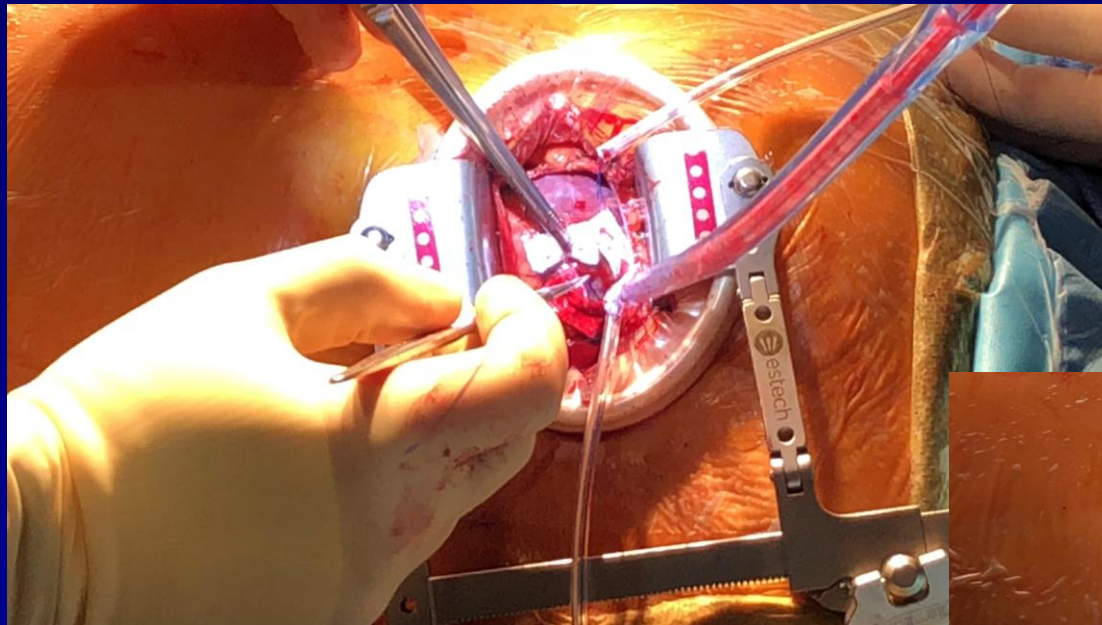
NeoChord Implantation



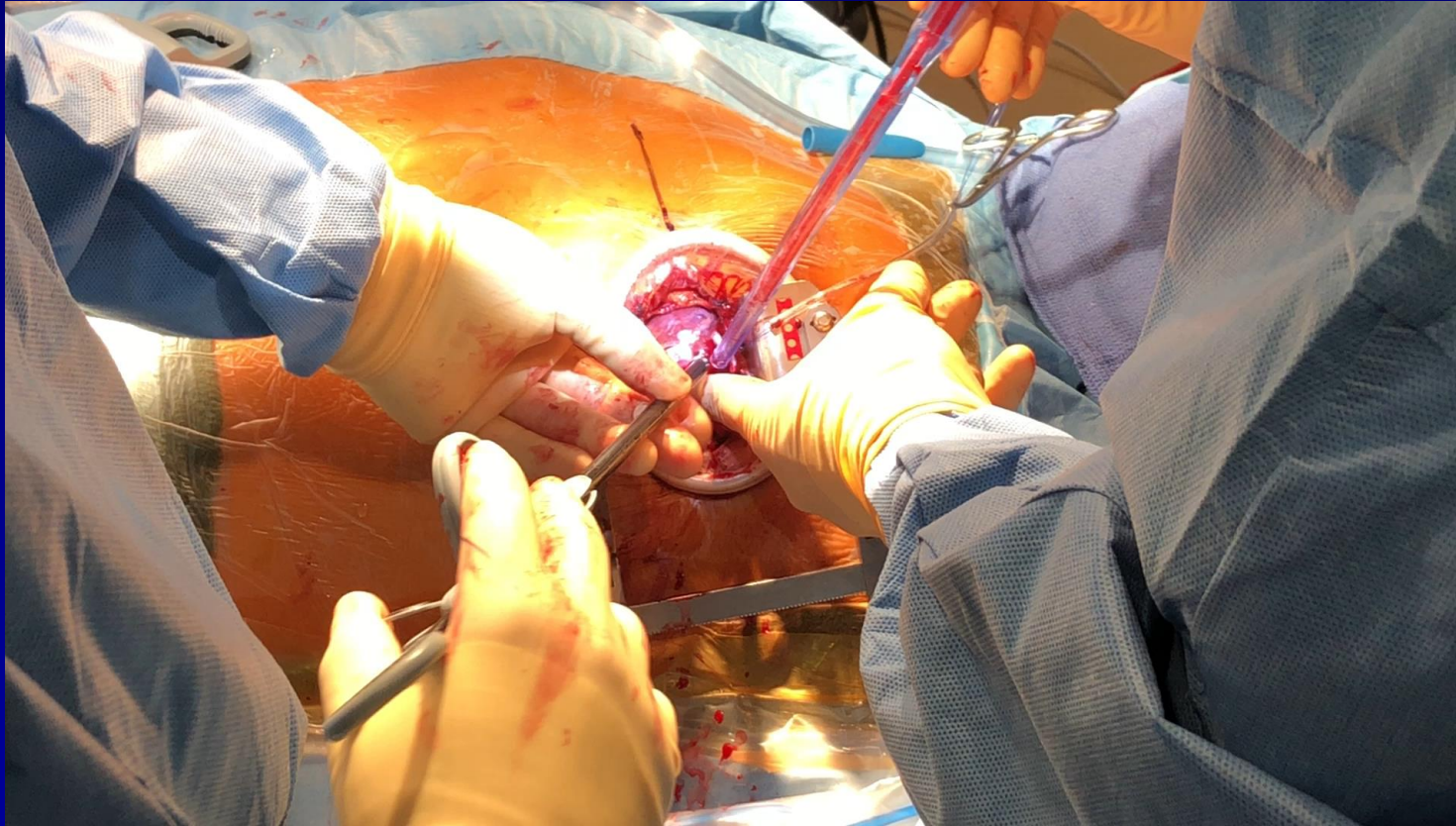
NeoChord Implantation



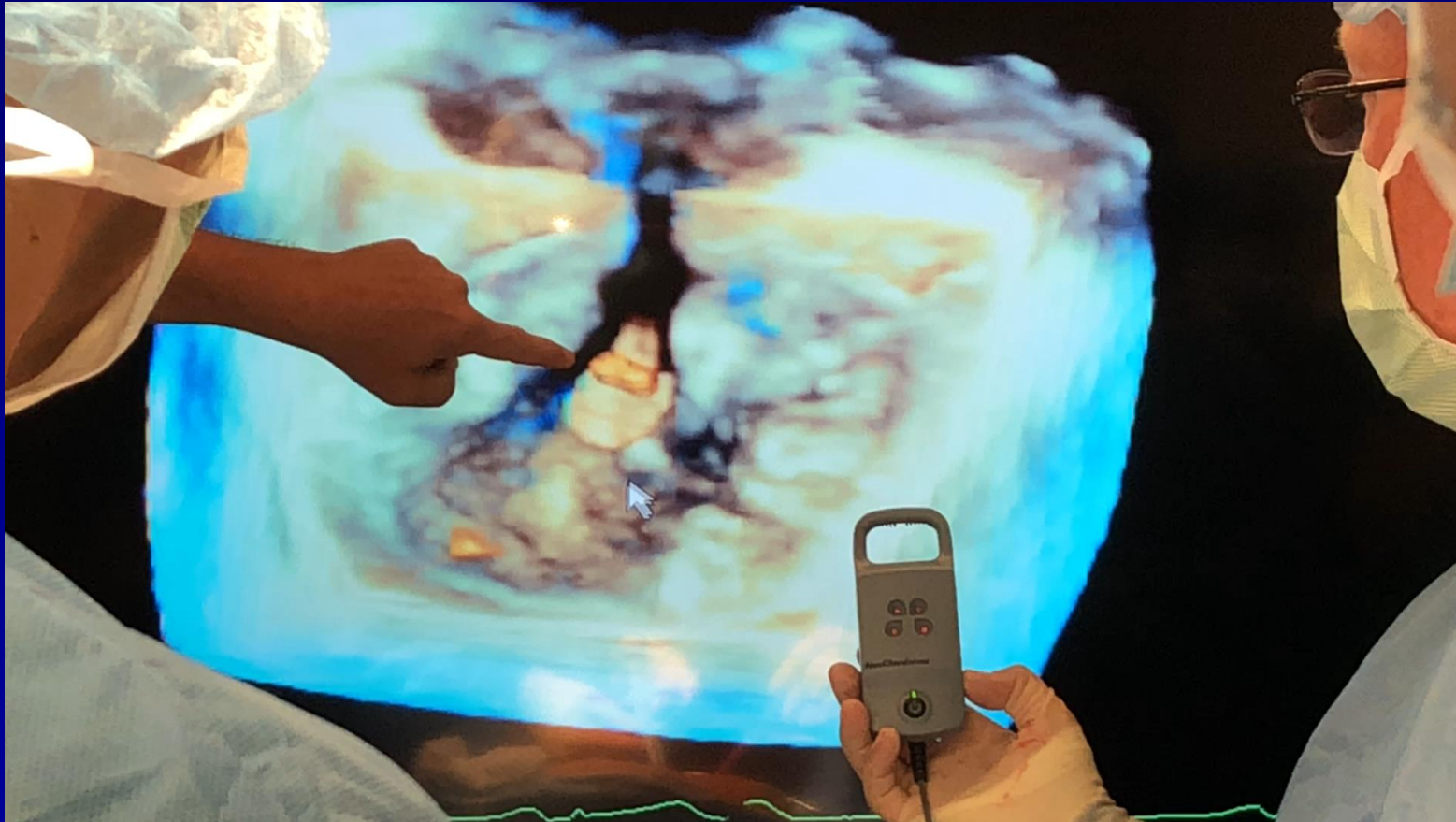
NeoChord Implantation



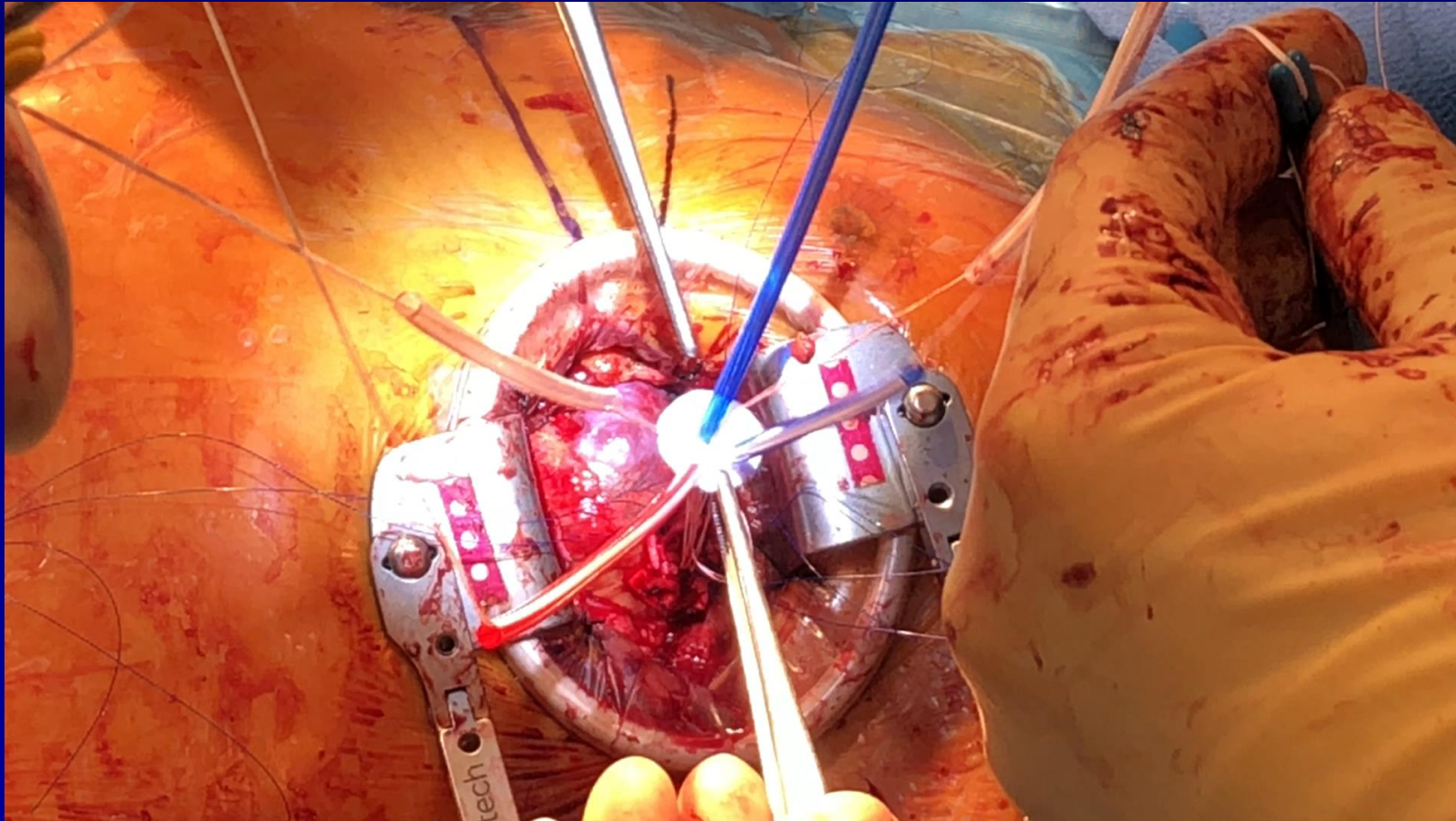
NeoChord Implantation



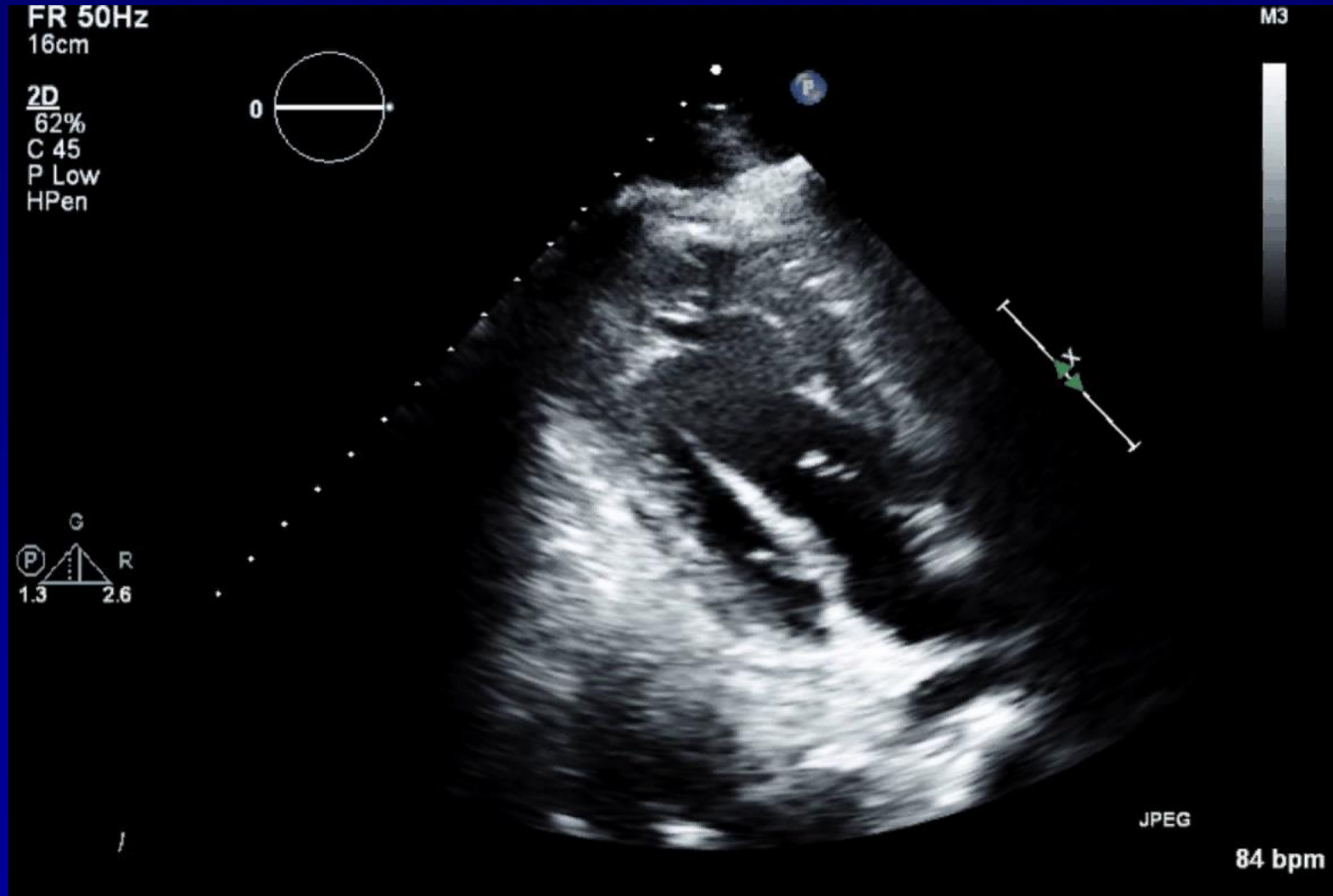
NeoChord Implantation



NeoChord Implantation

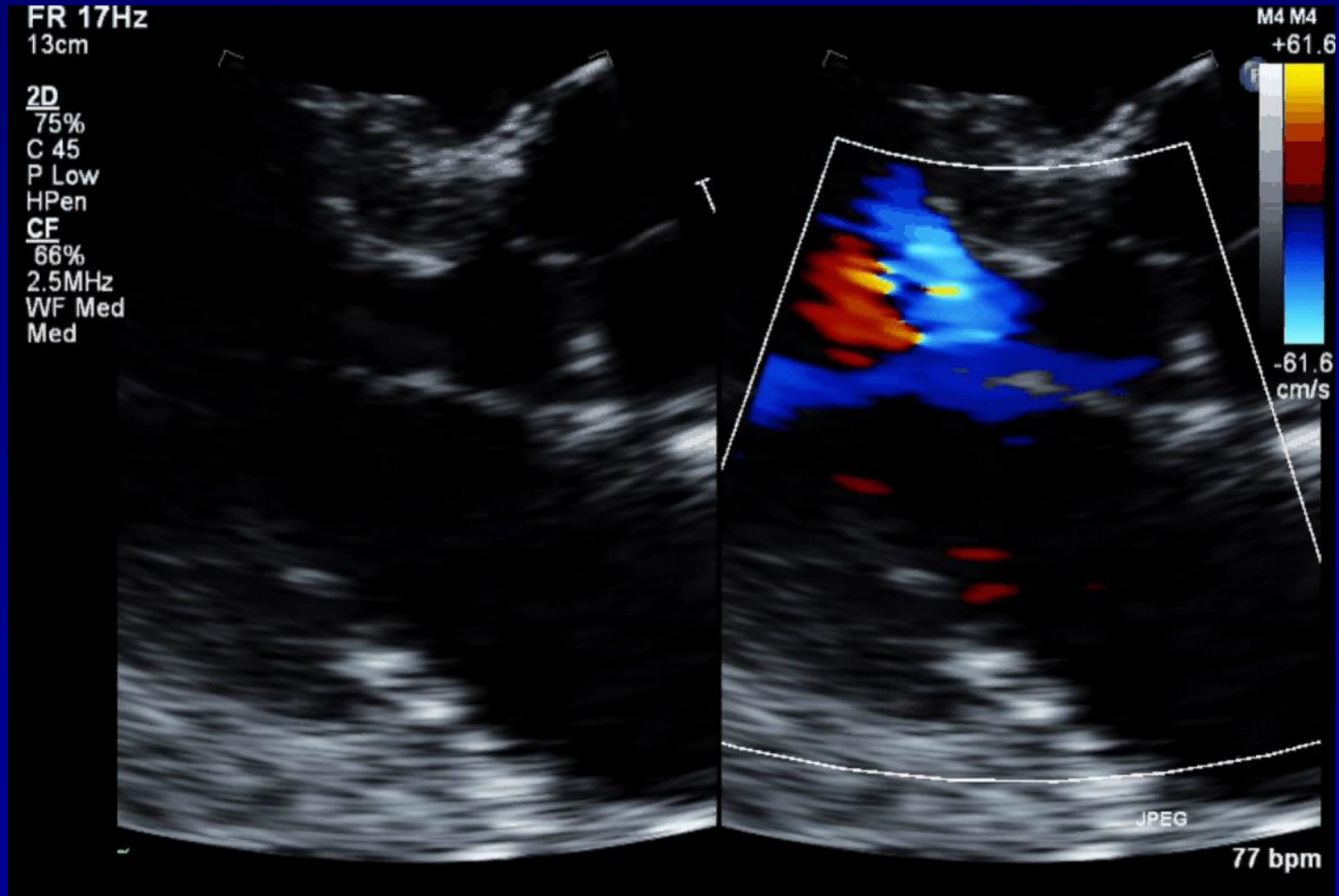


NeoChord Implantation



NeoChord Postop TTE

3 Months



Conclusions

- Initial experience with TA neochordal repair shows high feasibility and safety of the technique
- Device failure and complications were seen mainly during the first period after implantation while clinical stability was shown beyond follow-up
- Efficacy was maintained up to 1 year showing significant clinical benefit
- Better patients selection improve outcomes



GEORGETOWN UNIVERSITY

Thanks

Vinod H. Thourani, MD

404-274-3136

vinod.h.thourani@medstar.net

Harpoon Edwards

Patient Characteristics

PT#	Sex	Age	STS-Risk ²	NYHA ²	LVEF
			Score	Class	
1	F	65	0.76	II	65
2	M	68	1.09	III	50
3	M	63	0.60	II	70
4	M	57	0.69	II	60
5	M	42	0.22	II	60
6	M	63	0.46	II	60
7	M	59	0.34	I	55
8	M	89	4.57	III	73
9	M	82	2.50	II	54
10	M	73	1.41	I	65
11	M	51	0.21	III	65
12	M	66	0.58	III	57
13	M	80	1.50	III	79
MEAN		66.0	1.15		63

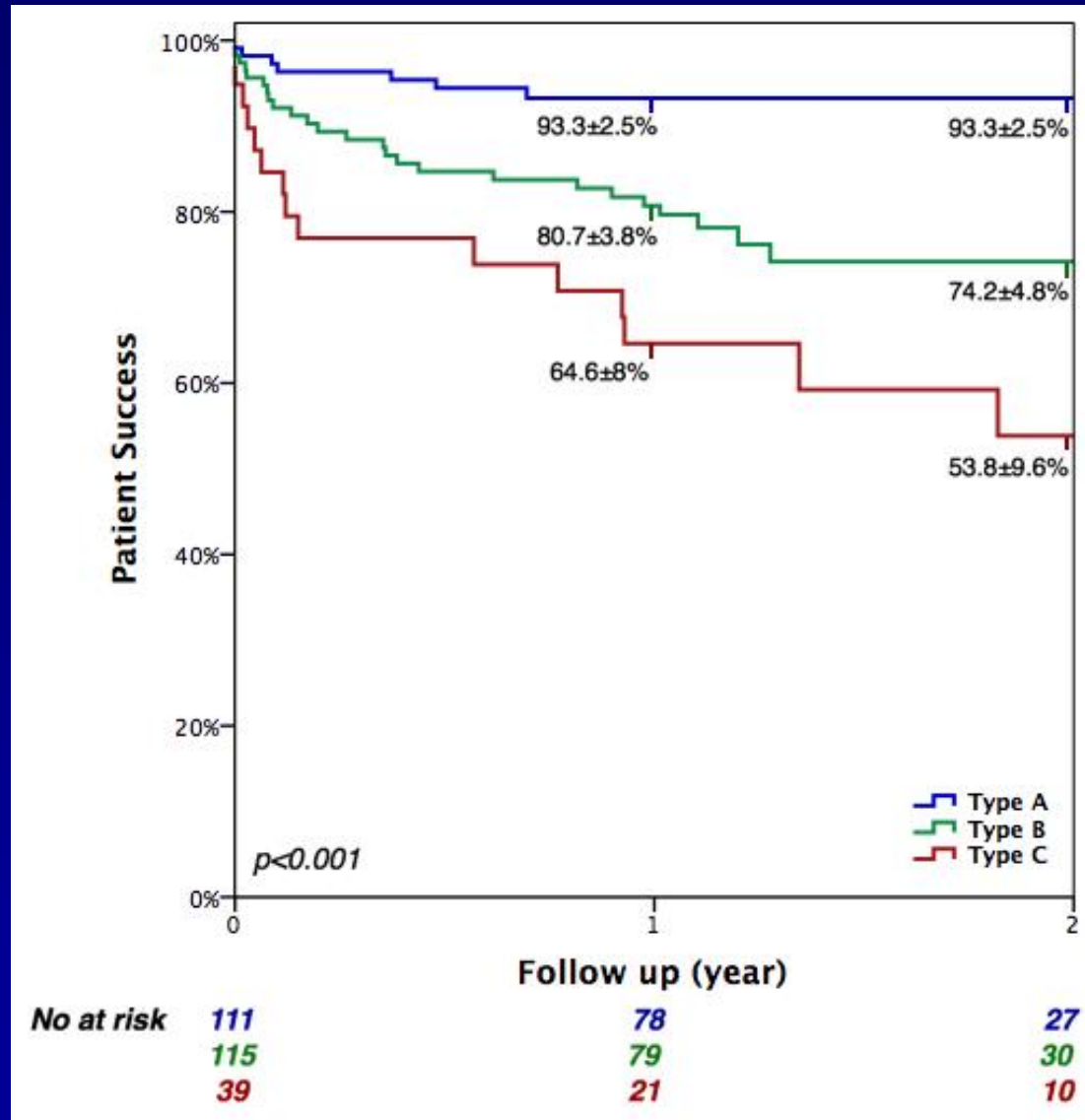
Excellent Safety Profile

- **No Mortality**
- **No Stroke**
- **No Renal Failure**
- **No Myocardial Infusion**
- **No Blood Transfusion**
- **No New Onset Post-Op AFib**

Echo Follow-Up

	Days Post Procedure	Number of Chords	Total Chord Days	Screening / Baseline	30 Days	6 Months	12 Months
1	562	4	2,248	Severe	Mild	None/Trace	None/Trace
2	560	3	1,680	Severe	None/Trace	Moderate	Moderate
3	510	3	1,530	Severe	None/Trace	None/Trace	None/Trace
4	72	4	288	Severe	Moderate	Converted to open surgery	
5	460	3	1,380	Severe	None/Trace	None/Trace	None/Trace
6	405	4	1,620	Severe	Moderate	Moderate	Moderate
7	404	4	1,616	Severe	Mild	Mild	Mild
8	359	3	1,077	Severe	Mild	None/Trace	
9	359	5	1,795	Severe	Mild	Mild	
10	231	3	693	Severe	Mild	Severe - converted to open surgery	
11	307	4	1,228	Severe	None/Trace	Mild	
12	211	4	844	Severe	Mild	Mild	
13	211	4	844	Severe	None/Trace	None/Trace	

NeoChord Patient Success



Type A

Type B

Type C

Nov 2013 to May 2017
7 European Centers

265 consecutive patients
included



Clinical follow-up at 1 year
(N=194 eligible subjects)



Clinical follow-up at 2 years
(N=79 eligible subjects)

NeoChord Overall Mitral Regurgitation

